

CASE REPORT

Incidental Discovery of a Cardiac Thrombus Mimicking a Right Atrial Myxoma in a Young Female Patient – A Case Report

Monica Alexandra Oltean, Bogdan Caloian, Diana Andrada Irimie, Dana Pop

Cardiology–Rehabilitation Department, “Iuliu Hațieganu” University of Medicine and Pharmacy, Cluj–Napoca, Romania

ABSTRACT

Introduction: Cardiac masses are at the attention of health specialists since the development of echocardiography. Even though imaging is an excellent tool for diagnosis, the clinical presentation, risk factors, and hemodynamic status of the patients are important in establishing the diagnosis and subsequent management. The purpose of this presentation is to assess the difficulty of diagnosis in the case of an intracardiac mass and its therapeutic management.

Case report: A 29-year-old female with paresthesia in the left arm and a systolic tricuspid murmur underwent echocardiography, which revealed a mass of 35/20 mm in the right atrium. Due to the high embolic risk, the patient was referred to the cardiac surgery department and underwent surgical removal of the cardiac mass, which presented the macroscopical aspect of a myxoma. However, the histopathological examination revealed a right atrial thrombus. **Conclusion:** Right heart thrombi represent a challenging diagnosis that involves a multidisciplinary team for the diagnosis and treatment of the patient.

Keywords: cardiac masses, atrial thrombus, myxoma

ARTICLE HISTORY

Received: December 29, 2022

Accepted: February 11, 2023

CORRESPONDENCE

Bogdan Caloian

Str. Viilor nr. 46–50

400066 Cluj–Napoca, Romania

Tel: +40 264 207 021

Email: bogdan.caloian@gmail.com

INTRODUCTION

When referring to right atrium masses, the differential diagnosis includes thrombi, primary or secondary cardiac tumors, and tricuspid valve vegetations.¹ Cardiac thrombus is likely underdiagnosed since only symptomatic patients are referred for diagnosis and is clinically relevant because of its potential complications.^{1,2} There are no guidelines for the management of right atrial thrombi because of the scarcity of studies regarding this condition.³

CASE PRESENTATION

A 29-year-old female presented to the cardiology department with paresthesia in the left arm in the last 4–5 days. She had a history of hypothyroidism with substitutive treatment and was a smoker of 15 cigarettes per day for 5 years. The cardiac examination revealed a regular cardiac rhythm, a systolic tricuspid murmur, and no signs of congestion. The electrocardiogram showed sinus rhythm, heart rate of 60 beats/min, QRS axis at 0 degrees, and negative T waves in DIII. The laboratory tests revealed

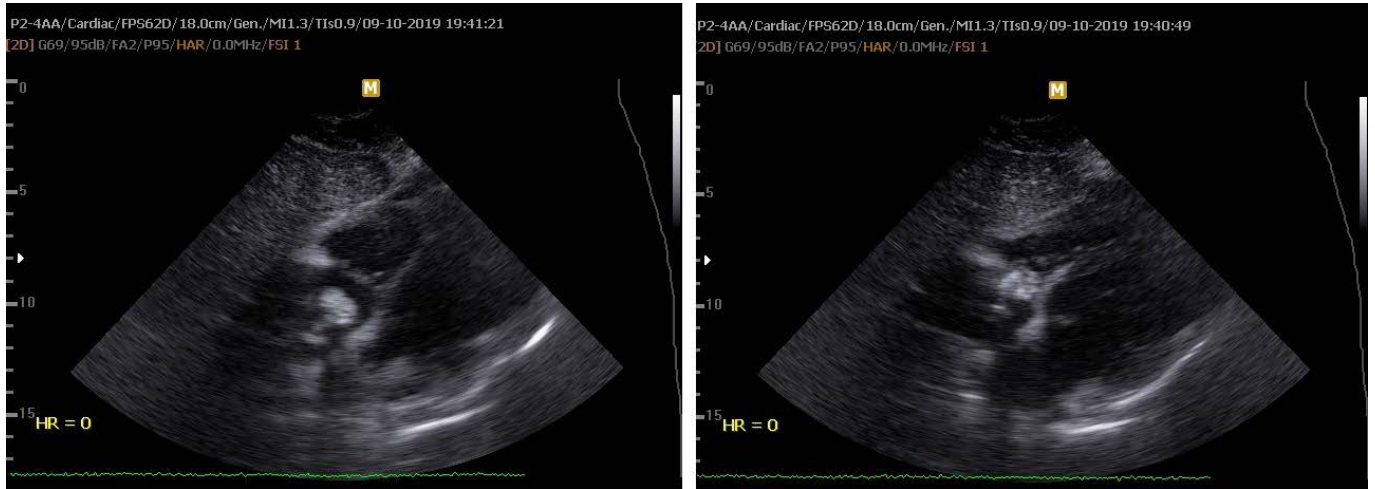

FIGURE 1. Images of transthoracic echocardiography, subcostal view, showing an inhomogeneous mass in the right atrium that prolapses in the right ventricle during diastole

iron deficiency anemia (hemoglobin at 10.2 g/dL) and thrombocytosis at 561,000/ μ L. Transthoracic echocardiography revealed an echogenic, inhomogeneous mobile mass of 35/20 mm, with irregular contour, attached to the interatrial septum through a small pedicle (Figure 1).

For a better view of the mass, transesophageal echocardiography was performed, which revealed, in bicaval view, a polylobate mass of 32/21 mm at the right atrium level. The mass was highly mobile, inhomogeneous, and with a pedicle most likely attached to the interatrial septum at the level of the inferior vena cava, suggestive for a cardiac myxoma (Figure 2).

The patient was referred to the cardiac surgery department because of the very high embolic risk of the cardiac mass. The Heart Team decided on immediate surgery.

After the institution of the cardiopulmonary bypass, the right atrium was opened, and the large mass was removed. Macroscopic inspection of the tumor showed a friable solid mass that measured 30/20 mm, with a small implantation base, towards the interatrial septum, at the level of the inferior vena cava, with a macroscopical aspect of myxoma. The patients also had a patent foramen ovale, which was closed by direct suture.

The histopathological examination revealed a calcified amorphous pseudotumor which corresponded to a right atrial thrombosis with major calcifications. There were no microscopic arguments for a cardiac myxoma.

Direct oral anticoagulant treatment was started after the histopathological result, and the patient was investigated comprehensively for antiphospholipid syndrome,

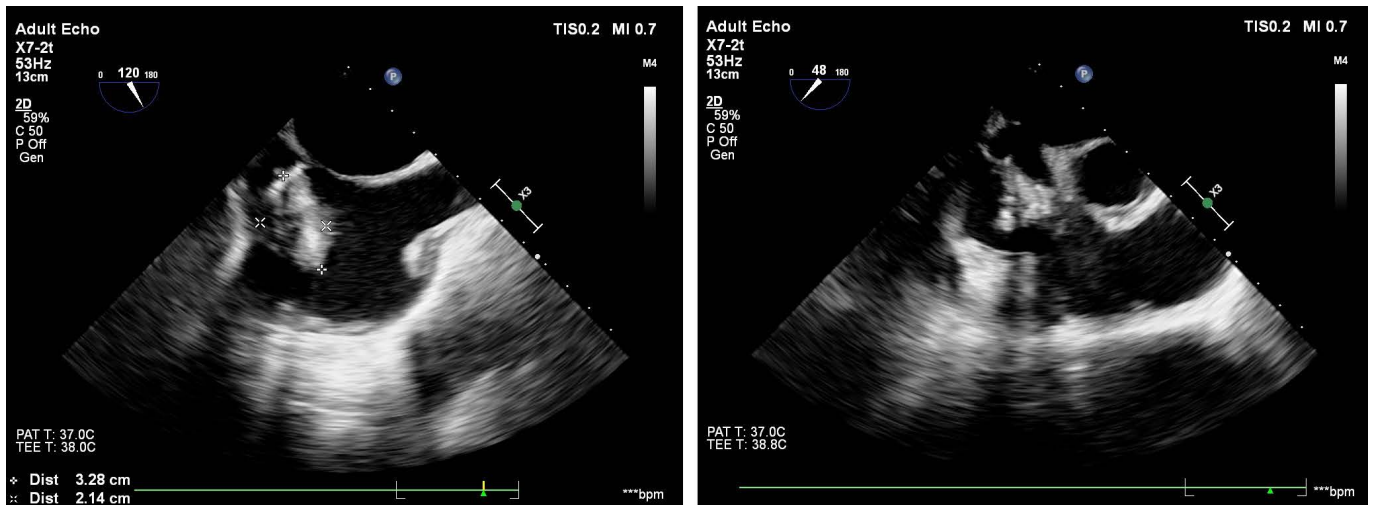


FIGURE 2. Image of transesophageal echocardiography showing a mass of 32/21 mm in the right atrium, most likely attached to the interatrial septum at the level of the inferior vena cava

including lupus anticoagulant, IgG and IgM subtype of anticardiolipin antibodies, anti-b2 glycoprotein-I antibody of IgG, IgM, IgA, which were all negative. Also, we searched for inherited thrombophilia, testing protein C, protein S, antithrombin III, and factor V Leiden mutation, prothrombin mutation, and methylenetetrahydrofolate reductase (MTHFR) gene mutation (with specific variants C677T mutation and A1298C mutation), which were negative, except for heterozygous A1298C mutation. The evolution thereafter was favorable, and at the cardiology follow-up at 6 months, the transthoracic echocardiography showed the absence of thrombus recurrence.

DISCUSSION

DIAGNOSIS OF CARDIAC MASSES

Cardiac masses have captured the attention of specialists since the beginning of cardiac imaging, and the vast majority are discovered incidentally during cardiac echocardiography.^{4,5}

The differential diagnosis of right atrial masses includes vegetations, tumors, and thrombi.^{6,7} The most common primary cardiac tumor is atrial myxoma.⁵ Fifteen percent of atrial myxomas are found in the right atrium, usually attached to the interatrial septum.^{8–10} While typical myxomas are easier to diagnose, some may have atypical features that make the diagnosis challenging.^{11–14} A possible cause of secondary tumors in the right atrium can be the extension of an intraabdominal tumor, like a hepatocellular carcinoma or renal cell carcinoma with a direct invasion of the inferior vena cava and the right atrium.^{4,15}

Even though data regarding right atrial thrombosis are scarce, a review from Sweden reported a prevalence of right atrium thrombi of 7% in 23,796 autopsies.⁴ It is well known that thrombus formation is less common in the right atrium than the left one, mainly because of its morphology, which is broad-based and less deep.¹⁶

Predisposing factors for thrombus formation are vascular catheters, pacemaker leads, and prosthetic tricuspid valves. Also, Behcet's disease should be ruled out in the diagnosis algorithm of a patient with a cardiac mass. In Behcet's disease, the thrombus is usually heterogeneous and echogenic, more commonly located in the right ventricle.^{17,18} There are also cases described in the literature of thrombus in the right atrium and the right atrial appendage among patients with atrial fibrillation, classical homocystinuria, and hypercoagulable states such as antiphospholipid syndrome or thrombophilia.¹⁹

While ventricular thrombi are generally detected by transthoracic echocardiography, transesophageal echocardiography is highly accurate for identifying atrial thrombi. Echocardiography has many advantages, being a low-cost imaging modality for detecting cardiac masses. With the help of echocardiography, we can determine the characteristics of a mass, such as dimensions, mobility, attachment, location, and echogenicity, which can help us differentiate between a benign or malignant nature of the mass.²⁰ New methods, such as 3D echocardiography and contrast echocardiography, are useful tools for the assessment of intracardiac masses.²⁰

The European Working Group on Echocardiography proposed a new classification for right atrial thrombi, into three groups. Type A refers to right atrial thrombi originating from the deep venous system and are usually described like large clots that are free-floating, also called "in transit". Type B describes right atrial thrombi in situ, usually small clots attached to the intracardiac devices or to the atria wall. Type C defines mobile in situ thrombi, which may resemble an atrial myxoma and typically have a thin point of attachment to the atrial wall. Regarding the complications, like the risk of embolization and prognosis, it varies by type and is linked to the mobility and dimension of the thrombus.¹⁶

For better detection and characterization of cardiac thrombi, several imaging modalities have been proven useful including transesophageal echocardiography, contrast-enhanced computed tomography, or cardiac magnetic resonance imaging (MRI). When comparing these imaging modalities, transesophageal echocardiography is superior to contrast-enhanced computed tomography for displaying atrial thrombi. Cardiac MRI is extremely important for the evaluation of tissue characteristics and the differential diagnosis between cardiac masses.²¹

The main differential diagnosis in the presented case was between myxoma and thrombus. Cardiac MRI examination could have differentiated between these two masses. The main MRI features of myxoma versus cardiac thrombus include: a) attachment pattern: narrow, often pediculated for myxoma and broad-based for thrombus; b) pattern of gadolinium enhancement: for myxoma – heterogeneous pattern of enhancement and for thrombus – the enhancement is extremely uncommon, unless a very organized thrombus with a high level of fibrous tissue is present; c) concerning the mobility of the cardiac mass, the myxoma is usually very mobile, with the prolapse of the lesion through the atrioventricular valve, while the thrombus is less mobile.⁶

The histopathological examination reported the presence of calcium in our patient's mass. When referring to

the differential diagnosis, studies report that calcifications occur more frequently in myxomas, but they have also been reported in cardiac thrombi.²

Regarding the patient's heterozygous MTHFR mutation, it was proven that a reduced enzyme function of MTHFR does not necessarily lead to an increase in homocysteine in all subjects and can be associated with normal homocysteine levels. Until this moment, the pathophysiological mechanisms concerning the relationship between hyper-homocysteinemia and cardiovascular risk are not fully understood.²² An MTHFR mutation that is not associated with elevated homocysteine levels is not a risk factor for cardiovascular diseases. There is no specific treatment for subjects with deep vein thrombosis, pulmonary embolism, cardiovascular disease, or pregnancy complications who present heterozygous MTHFR mutation and normal homocysteine levels.^{22,23} A right atrial thrombus in a young patient should raise the suspicion of a genetic predisposition even in the presence of risk factors for thrombus formation such as smoking.

The main complication of thrombi in the right heart is pulmonary thromboembolism, but sudden death may also occur. Hemodynamically, cardiac masses can lead to intracavitary obstruction or valvular dysfunction.^{1,24}

THERAPY OF RIGHT ATRIAL THROMBUS

Right heart thrombosis can lead to life-threatening complications if not detected and treated appropriately. The treatment for right atrial thrombus is based on anticoagulants, thrombolytic agents, or surgical thrombectomy, depending on thrombus dimensions, morphology, potential complications, and hemodynamic status.^{8,25,26} Until this moment, there is no consensus in the specialized literature regarding the best therapeutic approach.^{3,22,26,27}

In an article written by Chartier *et al.*, concerning a small series of patients diagnosed with free-floating thrombi in the right cardiac chambers, in-hospital mortality was high regardless of the therapeutic strategy. Also, most patients required urgent surgery, and fibrinolysis was only used as a therapeutic bridge in selected cases.²⁸

Indications for surgery are massive cardiac thrombosis, recurrent cardiac thrombosis after medical treatment, or association with cardiac congestion.^{2,17} Given the large size of our patient's mass and its polypoid and mobile appearance on echocardiography, which seemed to place our case at high risk for pulmonary embolism, we referred the patient to the cardiovascular surgery department. Moreover, the pathologic features of an organized thrombosis with calcified deposits, which could constitute the nucleus

for further thrombus formation, supported the surgical approach in our case.²

Rose *et al.* reported that patients with right heart thrombi have a mortality rate of up to 27.1%. The therapeutic management with thrombolysis led to better survival rates compared to anticoagulation or surgery, but further studies are needed to determine the best therapeutic approach.²⁹

A multidisciplinary team is the cornerstone for successful diagnosis, treatment, and follow-up of this risky clinical condition.³⁰

CONCLUSION

The diagnosis and management of cardiac masses is a challenge, especially in patients with a high risk of complications, when urgent and proper care is mandatory. In the absence of an evidence-based guideline to approach right atrial thrombi, management should be individualized for each patient, based on the dimensions and type of thrombi, hemodynamic status, and complications such as pulmonary embolism or heart failure. Right atrial thrombus is an underdiagnosed condition with a high mortality rate, and the best management modality has not yet been established.

CONFLICT OF INTEREST

Nothing to declare.

REFERENCES

1. Benjamin MM, Afzal A, Chamogeorgakis T, Feghali GA. Right atrial thrombus and its causes, complications, and therapy. *Proc (Bayl Univ Med Cent)*. 2017;30:54–56. doi: 10.1080/08998280.2017.11929526.
2. Cianciulli TF, Saccheri MC, Redruello HJ, et al. Right Atrial Thrombus Mimicking Myxoma with Pulmonary Embolism in a Patient with Systemic Lupus Erythematosus and Secondary Antiphospholipid Syndrome. *Tex Heart Inst J*. 2008;35:454–457.
3. Aroke D, Nnaoma CB, Nubong TF, Okoye OC, Visveswaran G. Right Atrial Thrombi, the Management Conundrum: 2 Case Reports. *Am J Case Rep*. 2021;22:e933427. doi: 10.12659/AJCR.933427.
4. Panidis IP, Kotler MN, Mintz GS, Ross J. Clinical and echocardiographic features of right atrial masses. *Am Heart J*. 1984;107:745–758. doi: 10.1016/0002-8703(84)90324-7.
5. Tyebally S, Chen D, Bhattacharyya S, et al. Cardiac Tumors: JACC CardioOncology State-of-the-Art Review. *JACC CardioOncol*. 2020;2:293–311. doi: 10.1016/j.jaccao.2020.05.009.
6. Lee PT, Hong R, Pang PY, Chua YL, Ding ZP. Clinical presentation of cardiac myxoma in a Singapore national cardiac centre. *Singapore Med J*. 2021;62:195–198. doi: 10.11622/smedj.2020041.

7. Sanjeev OP, Nath SS, Malviya D, Rajput SS. Right atrial myxoma: Unusual location; un-common association. *Ann Card Anaesth.* 2018;21:437-439. doi: 10.4103/aca.ACA_130_17.
8. Cohen A, Donal E, Delgado V, et al. EACVI recommendations on cardiovascular imaging for the detection of embolic sources: endorsed by the Canadian Society of Echocardiography. *Eur Heart J Cardiovasc Imaging.* 2021;22:e24-e57. doi: 10.1093/ehjci/jeab008.
9. Sanjeev OP, Nath SS, Malviya D, Rajput SS. Right atrial myxoma: Unusual location; un-common association. *Ann Card Anaesth.* 2018;21:437-439. Doi: 10.4103/aca.ACA_130_17.
10. Longatto FC, Santos TSAP, Soares MJM, et al. Upper vena cava syndrome secondary to gi-ant atrial myxoma. *Rev Assoc Med Bras (1992).* 2018;64:1077-1080. doi: 10.1590/1806-9282.64.12.1077.
11. Flint N, Siegel RJ, Bannykh S, Luthringer DJ. Bi-atrial cardiac myxoma with glandular dif-ferentiation: a case report with detailed radiologic-pathologic correlation. *Eur Heart J Case Rep.* 2018;2:yty045. doi: 10.1093/ehjcr/yty045.
12. Durand P, Furudoi A, Parrens M, Lazaro E, Viallard JF, Rivière E. Complete remission of immune thrombocytopenia in a 30-year old woman after excision of a right atrial myxoma. *Br J Haematol.* 2019;187:e18-e19. doi: 10.1111/bjh.16135.
13. Beiras-Fernandez A, Kornberger A, El-Beyroui H, Vahl CF. Giant right atrial myxoma: A rare cause of cardiovascular collapse. *SAGE Open Med Case Rep.* 2019;7:2050313X19841461. doi: 10.1177/2050313X19841461.
14. Merli VN, Dell'Oglio S, Grazioli V, et al. Surgical Treatment for Pulmonary Embolization of a Right Atrial Myxoma. *Ann Thorac Surg.* 2019;107:e245-e246. doi: 10.1016/j.athoracsur.2018.07.095.
15. Nawaz H, Chngal K, Hariri I, Idris O, Bhatti K. Asymptomatic spontaneous complete dis-lodgement of a right atrial myxoma. *Br J Hosp Med (Lond).* 2019;80:ii. doi: 10.12968/hmed.2019.80.5.ii.
16. Bergonti M, Ascione C, Agostoni P, Castelli R, Vignati C. Massive Right Atrial Thrombosis: Are You Brave Enough to Start Anticoagulation? A Case Report. *Front Cardiovasc Med.* 2021;8:688351. doi: 10.3389/fcvm.2021.688351.
17. Louali FE, Tamdy A, Soufiani A, et al. Cardiac thrombosis as a manifestation of Behçet syndrome. *Tex Heart Inst J.* 2010;37:568-571.
18. Diz Küçükaya R. Thrombosis in the antiphospholipid syndrome. *Turk J Haematol.* 2006;23:5-14.
19. Tan S, Rusk RA, Tan CY, Wilson SM. Demonstrable intracardiac thrombus in a new case of classical homocystinuria. *European Heart Journal – Cardiovascular Imaging.* 2017;18:iii354-iii358. doi: 10.1093/ehjci/jex292.
20. Mankad R, Herrmann J. Cardiac tumors: echo assessment. *Echo Res Pract.* 2016;3:R65-R77. doi: 10.1530/ERP-16-0035.
21. Turhan S, Ozcan UO, Erol C. Imaging of intracardiac thrombus. *Cor et Vasa.* 2013;55:e176-e183. doi: 10.1016/j.crvasa.2013.02.005.
22. Berkenbush M, Chan MY, Esposito A. Right Atrial Thrombus. *JETem.* 2019;4:V38-39. doi: 10.21980/J8F93V.
23. Moll S, Varga EA. Homocysteine and MTHFR Mutations. *Circulation.* 2015;132:e6-9. doi: 10.1161/CIRCULATIONAHA.114.013311.
24. Pandey AC, Carey JJ, Thompson JL. Right atrial myxoma presenting as a pulmonary embo-lism in a 32-year-old female. *JRSM Cardiovasc Dis.* 2019;8:2048004018817606. doi: 10.1177/2048004018817606.
25. Konstantinides SV, Meyer G, Becattini C, et al. 2019 ESC Guidelines for the diagnosis and management of acute pulmonary embolism developed in collaboration with the European Respiratory Society (ERS). *Eur Heart J.* 2020;41:543-603. doi: 10.1093/eurheartj/ehz405.
26. Lazar L, Dave R, Tabibiazar R. Dilemma of Right Atrial Thrombi, to Dissolve or to Extract. *Proceedings of UCLA Healthcare.* 2012;16.
27. Carda R, Almería C, Lennie V, Serra V, Zamorano JL. What to do with an atrial thrombus? *Eur J Echocardiogr.* 2008;9:204-205. doi: 10.1093/ejehocard/jem072.
28. Chartier L, Béra J, Delomez M, et al. Free-floating thrombi in the right heart: diagnosis, man-agement, and prognostic indexes in 38 consecutive patients. *Circulation.* 1999;99:2779-2783. doi: 10.1161/01.cir.99.21.2779.
29. Rose PS, Punjabi NM, Pearse DB. Treatment of right heart thromboemboli. *Chest.* 2002;121:806-814. doi: 10.1378/chest.121.3.806.
30. Selwanos PPS, Ahmed AO, El Bakry KM, et al. Management of a huge right atrial thrombus in a patient with multiple comorbidities. *Egypt Heart J.* 2020;72:79. doi: 10.1186/s43044-020-00112-x.