

ORIGINAL RESEARCH

Cardiac Magnetic Resonance Features Associated with the Risk of Cardiac Arrest in Patients with Acute Myocardial Infarction

Evelin Szabo^{1,2,3}, Lehel Bordi^{1,2}, Teofana Mihaila¹, Cristian Tolescu¹, Imre Benedek^{1,2,3}

¹ Clinic of Cardiology, Emergency Clinical County Hospital, Târgu Mureș, Romania

² “George Emil Palade” University of Medicine, Pharmacy, Science and Technology, Târgu Mureș, Romania

³ Center of Advanced Research in Multimodal Cardiac Imaging, Cardio Med, Târgu Mureș, Romania

ABSTRACT

Background: Cardiac arrest (CA) is the most severe complication of acute myocardial infarction (AMI). Besides the location and severity of coronary occlusion, different factors may have significant role in the pathogenesis of AMI-related cardiac arrest (CA), but their contribution is still under investigation. The aim of the study was to investigate the cardiac magnetic resonance (CMR) features of myocardial injury associated with a higher risk of CA accompanying an AMI. **Methods:** In total, 918 myocardial segments from 54 post-AMI patients undergoing CMR imaging with delayed gadolinium enhancement were enrolled in the study, of which 18.54% presented CA during the acute phase of AMI. In all patients, infarct mass, the proportion of high transmural extent, and scar mass at different myocardial segments were calculated using QMap software (Medis BV). **Results:** Compared to patients without CA, those with CA had a significantly higher infarct size ($p = 0.03$) and a higher degree of transmural extent (29.28% vs. 14.1%, $p = 0.01$). The risk of CA during the acute phase was significantly higher in patients in whom the location of myocardial injury was at the level of latero-apical, anterolateral, and basal anterior segments. Group 1 presented a larger infarct size at the level of the latero-apical (33.9 ± 30.6 g vs. 13.6 ± 17.3 g, $p = 0.02$), anterolateral (26.5 ± 29.0 g vs. 8.9 ± 12.8 g, $p = 0.02$), and anterobasal segment (20.1 ± 21.5 g vs. 7.8 ± 14.7 g, $p = 0.02$). **Conclusions:** CMR imaging identified infarct mass, high transmural extent, and large myocardial injury as features associated with an increased risk of CA in the acute phase of AMI, especially at the level of anterolateral segments.

Keywords: cardiac arrest, acute myocardial infarction, cardiac magnetic resonance, infarct size, infarct location

ARTICLE HISTORY

Received: September 15, 2022

Accepted: September 22, 2022

CORRESPONDENCE

Constantin Tolescu

Str. Gheorghe Marinescu nr. 50

540139 Târgu Mureș, Romania

Tel: +40 372 653 100

E-mail: cristi.tolescu95@gmail.com

INTRODUCTION

Despite significant advances in cardiology over the past few decades, sudden cardiac arrest (SCA) remains a major challenge in cardiovascular medicine. The identification of clinical characteristics associated with SCA may have a strong impact on patient management, in the attempt to reduce all-cause mortality in these critical cases.¹

Cardiac magnetic resonance (CMR) has the ability to noninvasively characterize the structure of the heart muscle tissue in a unique way, in parallel with measurement of the volumes and size of the replacement fibrosis.^{2,3} CMR is the gold-standard modality for structural and functional myocardial evaluation, being also able to provide extremely accurate information about tissue characterization. Late gadolinium enhancement (LGE) for replacement fibrosis, T1 imaging for interstitial fibrosis, and T2 imaging for myocardial edema/inflammation are the most frequently used methods in CMR imaging for the complex evaluation of post-myocardial patients.^{4,5}

CMR imaging is an important part of a diagnostic test in patients who have survived SCA.⁶ At the same time, CMR is important for risk assessment, treatment strategy, and long-term follow-up of patients with ischemic heart disease, including those with ST-elevation myocardial infarction (STEMI) to visualize and quantify permanent myocardial injury.⁷

It is well known that in patients with AMI, the size of myocardial necrosis and the transmural degree depends on many factors including the presence of collateral blood flow, the time between the first symptoms and completion of revascularization, and the effectiveness of revascularization.

The aim of this study was to investigate the CMR features of myocardial injury associated with a higher risk of cardiac arrest (CA) accompanying an acute myocardial infarction (AMI).

MATERIAL AND METHODS

STUDY POPULATION

This single-center, non-randomized, observational study was conducted in the Laboratory of Advanced Research in Cardiac Multimodal Imaging of the Cardio Med Medical Center, Târgu Mureș, Romania. In total, 54 patients with recent AMI were enrolled in the study. All patients underwent post-AMI CMR imaging with LGE, performed one month after the infarction to evaluate the infarct size and transmural index.

STUDY GROUPS

The study population was divided into two groups: group 1 – 8 patients who survived a CA in the acute phase of an AMI, and group 2 – 46 patients, matched for age and gender, with AMI but without CA. In all patients, infarct mass, the proportion of high transmural extent, and scar mass at different myocardial segments were calculated using Medis Suite 2.1 with the Qmass 8.1 application. The study protocol is illustrated in Figure 1.

CMR IMAGING AND LEFT VENTRICULAR ASSESSMENT

All CMR examinations were performed with commercially available 1.5 T Siemens Magnetom Aera MRI equip-

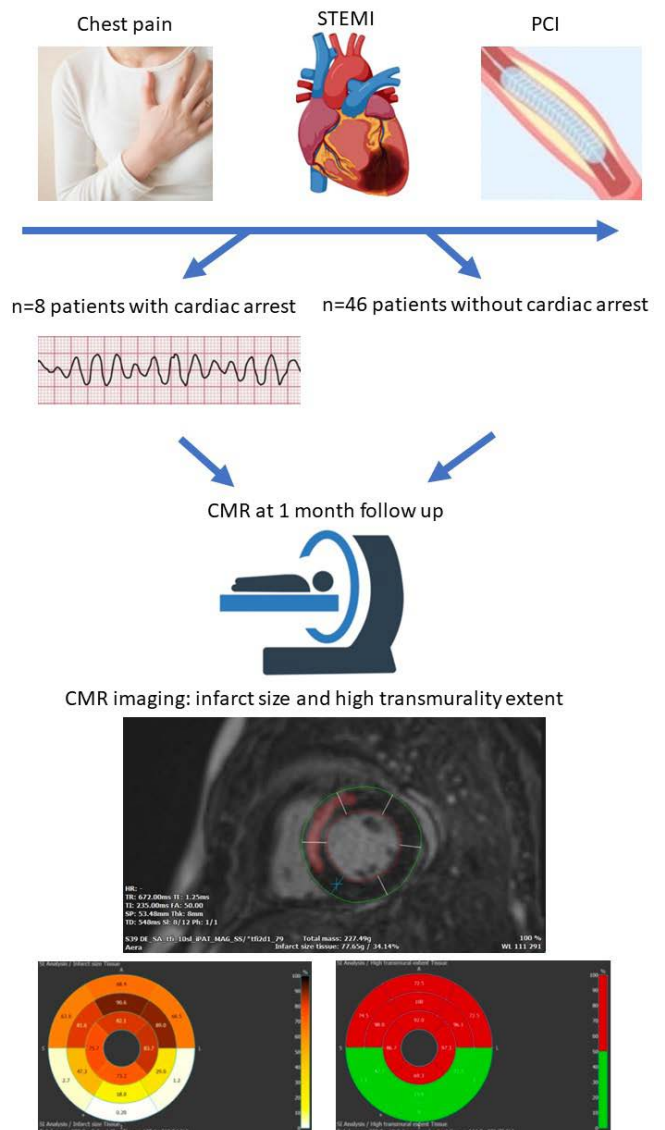


FIGURE 1. Diagram of the study protocol

ment (Siemens, Erlangen, Germany). CMR image series were used to calculate indexed left ventricular (LV) mass, LV ejection fraction (LVEF), LV end-diastolic volume (LVEDV), LV end-systolic volume (LVESV), and cardiac output (CO). Image post-processing was performed with Medis QMass 8.1 software (Medis, Leiden, the Netherlands). LGE image processing and delayed signal intensity (DSI) analysis were performed in 10–12 consecutive short-axis LGE images. For segmentation, full width at half maximum automated thresholding with hyperenhancement on LGE was used. Epi- and endocardial contours were drawn manually in short-axis images (excluding papillary muscles). The transmural threshold was set to 50%. The following CMR-derived parameters were determined: LV myocardium volume (mL), myocardium mass (g), infarct size volume (mL), infarct size mass (g), infarct size percentage (%), high transmural extent (mL), and high transmural extent (g).

STATISTICAL ANALYSIS

The collected data was statistically analyzed with Graph Pad InStat 3.10 software (GraphPad Software, Inc., San Diego, USA). Quantitative variables were expressed as mean \pm standard deviation, and binary variables as integer values and percentages. Unpaired Student's t-test and the Mann-Whitney test were used for comparison of continuous variables between groups, and Fischer's exact test was used for the comparison of categorical variables. The threshold for statistical significance was set at $p \leq 0.05$, and all statistical tests were two-sided.

ETHICS

The study protocol has been approved by the ethics committee of Cardio Med center and of the "George Emil Palade" University of Medicine, Pharmacy, Science and Technology. All study subjects provided written informed consent, and study procedures were carried out in accordance with the code of ethics of the World Medical Association's Declaration of Helsinki.

RESULTS

CLINICAL CHARACTERISTICS OF THE STUDY POPULATION

The clinical characteristics of the study population are presented in Table 1. There were no significant differences between CA and non-CA groups regarding age ($p = 0.8$), female gender ($p = 0.24$), and comorbidities such as hy-

TABLE 1. Clinical characteristics of the study population

	Group 1 CA group (n = 8)	Group 2 Non-CA group (n = 46)	p value
Age, years	55.6 \pm 15.5	56.7 \pm 11.63	0.8
Gender, female, n (%)	4 (50%)	13 (28.26%)	0.24
Hypertension, n (%)	4 (50%)	36 (78.26%)	0.18
Current smoking, n (%)	4 (50%)	21 (45.6%)	>0.9
Diabetes, n (%)	1 (12.5%)	10 (21.7%)	>0.9

pertension ($p = 0.18$), smoking status ($p = 0.9$), and diabetes mellitus type 2 ($p = 0.9$).

CMR DATA IN THE STUDY POPULATION

The CMR data in this study population are presented in Table 2. Compared to patients without CA, those with CA had a significantly higher infarct mass (47.9 \pm 38 g vs. 23.3 \pm 17.8 g, $p = 0.03$), infarct mass % (26.9 \pm 17.3% vs. 15.1 \pm 8.6%, $p = 0.02$), and a higher degree of transmurality (29.28 \pm 20.2% vs. 14.1 \pm 9.2%, $p = 0.01$) (Figure 2). The CMR results indicate that the risk of CA during the acute phase was significantly higher in patients in whom the location of myocardial injury was at the level of latero-apical, anterolateral, and anterobasal segments. Group 1 presented a larger infarct size at the level of the latero-apical (33.9 \pm 30.6 g vs. 13.6 \pm 17.3 g, $p = 0.02$), anterolateral (26.5 \pm 29.0 g vs. 8.9 \pm 12.8 g, $p = 0.02$), and anterobasal segment (20.1 \pm 21.5 g vs. 7.8 \pm 14.7 g, $p = 0.02$) (Figure 3).

DISCUSSION

Among the available imaging methods, CMR is considered the gold standard for determining infarct size and transmurality in STEMI patients.⁸ LGE CMR is the recommended approach to quantify infarct dimensions.⁹ In the case of AMI, the rupture of the heart muscle cells allows the diffusion of gadolinium-based agents into the intracellular space. This results in "hyperenhancement" of the infarcted area compared to healthy myocardium.¹⁰ The prognostic validity of CMR-determined acute infarct size is associated with other established clinical risk factors such as LVEF.

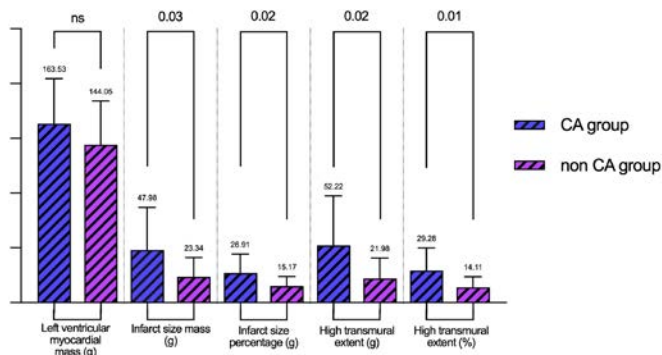
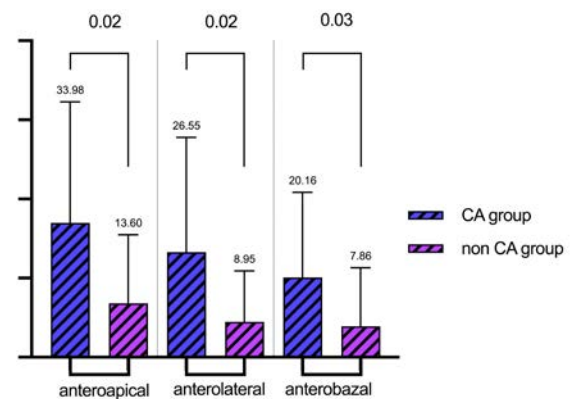
CMR markers are superior to clinical risk scores in assessing the presence or risk of LV dysfunction.¹¹ Therefore, infarct size assessment performed with LGE-CMR offers the possibility of more accurate clinical risk prediction in STEMI patients. Previous studies have confirmed that STEMI patients with myocardial injury at the level of

TABLE 2. CMR data in the study population

	Group 1 CA group (n = 8)	Group 2 Non-CA group (n = 46)	p value
Left ventricle myocardium mass (g)	164 ± 41	144 ± 40	0.2
Infarct size mass (g)	47.9 ± 38	23.3 ± 17.8	0.03
Infarct size percentage (%)	26.9 ± 17.3	15.1 ± 8.6	0.02
High transmural extent (g)	52.2 ± 45.2	21.9 ± 18.7	0.02
High transmural extent (%)	29.28 ± 20.2	14.1 ± 9.2	0.01
Infarct mass septal apical (g)	30.92 ± 35.5	32.18 ± 35.12	0.89
Infarct mass antero-apical (g)	30.13 ± 25.66	25.66 ± 28.47	0.69
Infarct mass latero-apical (g)	33.9 ± 30.6	13.6 ± 17.3	0.02
Infarct mass infero-apical (g)	25.8 ± 26.6	18.1 ± 23.7	0.39
Infarct mass mid anteroseptal (g)	32.9 ± 36.6	21.24 ± 25.1	0.6
Infarct mass mid anterior (g)	28.7 ± 35.5	12.8 ± 20.2	0.3
Infarct mass mid anterolateral (g)	26.5 ± 29	8.9 ± 12.8	0.02
Infarct mass mid inferolateral (g)	27.7 ± 30.02	18.9 ± 25.2	0.36
Infarct mass mid inferior (g)	21.5 ± 25.28	14.86 ± 20.4	0.84
Infarct mass mid inferoseptal (g)	22.3 ± 27.9	12.9 ± 17.16	0.36
Infarct mass basal anteroseptal (g)	18.25 ± 21.1	15.01 ± 17.08	0.77
Infarct mass basal anterior (g)	20.1 ± 21.5	7.8 ± 14.7	0.03
Infarct mass basal anterolateral (g)	18.6 ± 27.4	7.3 ± 14.3	0.47
Infarct mass basal inferior (g)	18.5 ± 25.3	15.4 ± 22.7	0.48
Infarct mass basal inferoseptal (g)	17.4 ± 20.06	18.8 ± 20.5	0.96

the anterior wall are at increased risk of adverse left ventricular remodeling, heart failure, and death.¹² However, it has not been clarified whether the worse outcome can be attributed to the specific characteristics of the infarct site alone in patients with anterior wall STEMI, or whether only these patients have a larger infarct size and transmurality.¹³ Our study indicates that there are several locations of myocardial necrosis which seem more prone to produce a CA, and these are located especially at the level of anterior and lateral segments.

The injection of stem cells in the ventricular myocardium of post-MI patients had a significant limitation resulting from the pro-arrhythmogenic effect of the stem cells, especially when intra-myocardial route is selected for injection instead of intra-arterial way.^{14,15} In light of the current study, if different myocardial segments have different arrhythmogenic potential, it can be speculated that the pro-arrhythmogenic effect of stem cells at the

**FIGURE 2.** Comparative analysis of LV mass, infarct size, and transmurality between study groups**FIGURE 3.** Patients with myocardial injury located in the antero-lateral, latero-apical, and anterior segments were more prone to develop cardiac arrest during the acute phase of AMI.

level of myocardial tissue may be avoided if the location of the injection is selected in areas less predisposed to CA.

In our study, patients with a large myocardial scar in the anterolateral segments had a higher incidence of CA in the acute phase, suggesting the existence of a causal relationship between necrosis location and the risk of sudden death. This may explain why patients with myocardial infarction of limited severity may develop CA if the location of the myocardial necrosis is in an area predisposed to arrhythmic complications.

CONCLUSION

Myocardial mass, high transmural extent at CMR imaging, and a large myocardial injury identified by CMR at the anterior and lateral ventricular segments level seem to be associated with an increased risk of CA in the acute phase of AMI.

CONFLICT OF INTEREST

Nothing to declare.

ACKNOWLEDGEMENT

This research was funded by the CARDIOCOV project – “Prototype for personalized assessment of cardiovascular risk and post-Covid myocarditis based on artificial intelligence, advanced medical imaging and cloud computing” – financed by UEFISCDI PN-III-P2-2.1-PTE-2021-0450.

REFERENCES

- Zareba W, Zareba KM. Cardiac Magnetic Resonance in Sudden Cardiac Arrest Survivors. *Circ Cardiovasc Imaging*. 2017;10:e007290. doi: 10.1161/CIRCIMAGING.117.007290.
- White JA, Fine NM, Gula L, et al. Utility of cardiovascular magnetic resonance in identifying substrate for malignant ventricular arrhythmias. *Circ Cardiovasc Imaging*. 2012;5:12-20. doi: 10.1161/CIRCIMAGING.111.966085.
- Eitel I, Desch S, de Waha S, et al. Long-term prognostic value of myocardial salvage assessed by cardiovascular magnetic resonance in acute reperfused myocardial infarction. *Heart*. 2011;97:2038-2045. doi: 10.1136/heartjnl-2011-300098.
- Wong TC, Piehler KM, Zareba KM, Lin K, et al. Myocardial Damage Detected by Late Gadolinium Enhancement Cardiovascular Magnetic Resonance Is Associated With Subsequent Hospitalization for Heart Failure. *JAHA*. 2013;2:e000416. doi: 10.1161/JAHA.113.000416.
- Messroghli DR, Moon JC, Ferreira VM, et al. Clinical recommendations for cardiovascular magnetic resonance mapping of T1, T2, T2* and extracellular volume: A consensus statement by the Society for Cardiovascular Magnetic Resonance (SCMR) endorsed by the European Association for Cardiovascular Imaging (EACVI). *J Cardiovasc Magn Reson*. 2017;19:75. doi: 10.1186/s12968-017-0389-8.
- Rodrigues P, Joshi A, Williams H, et al. Diagnosis and Prognosis in Sudden Cardiac Arrest Survivors Without Coronary Artery Disease: Utility of a Clinical Approach Using Cardiac Magnetic Resonance Imaging. *Circ Cardiovasc Imaging*. 2017;10:e006709. doi: 10.1161/CIRCIMAGING.117.006709.
- Emrich T, Halfmann M, Schoepf UJ, Kreitner KF. CMR for myocardial characterization in ischemic heart disease: state-of-the-art and future developments. *Eur Radiol Exp*. 2021;5:14. doi: 10.1186/s41747-021-00208-2.
- Reindl M, Eitel I, Reinstadler SJ. Role of Cardiac Magnetic Resonance to Improve Risk Prediction following Acute ST-elevation Myocardial Infarction. *J Clin Med*. 2020;9:1041. doi: 10.3390/jcm9041041.
- Schulz-Menger J, Bluemke DA, Bremerich J, et al. Standardized image interpretation and post-processing in cardiovascular magnetic resonance – 2020 update: Society for Cardiovascular Magnetic Resonance (SCMR): Board of Trustees Task Force on Standardized Post-Processing. *J Cardiovasc Magn Reson*. 2020;22:19. doi: 10.1186/s12968-020-00610-6.
- Moosa S, Ntusi N. Role of cardiovascular magnetic resonance in the evaluation of cardiomyopathy. *South African Journal of Radiology*. 2016;20:1-10. doi: 10.4102/sajr.v20i2.1055.
- Eitel I, de Waha S, Wöhrle J, et al. Comprehensive prognosis assessment by CMR imaging after ST-segment elevation myocardial infarction. *J Am Coll Cardiol*. 2014;64:1217-1226. doi: 10.1016/j.jacc.2014.06.1194.
- Reindl M, Reinstadler SJ, Tiller C, Feistritz HJ, Kofler M, Brix A, Mayr A, Klug G, Metzler B. Prognosis-based definition of left ventricular remodeling after ST-elevation myocardial infarction. *Eur Radiol*. 2019;29:2330-2339. doi: 10.1007/s00330-018-5875-3.
- Frantz S, Hundertmark MJ, Schulz-Menger J, Bengel FM, Bauersachs J. Left ventricular remodelling post-myocardial infarction: pathophysiology, imaging, and novel therapies. *Eur Heart J*. 2022;43:2549-2561. doi: 10.1093/eurheartj/ehac223.
- Benedek I, Bucur O, Benedek T. Intracoronary Infusion of Mononuclear Bone Marrow-Derived Stem Cells is Associated with a Lower Plaque Burden After Four Years. *J Atheroscler Thromb*. 2014;21:217-229. doi: 10.5551/jat.19745.
- Gyöngyösi M, Hemetsberger R, Posa A, et al. Hypoxia-inducible factor 1- α release after intracoronary versus intramyocardial stem cell therapy in myocardial infarction. *J Cardiovasc Transl Res*. 2010;3:114-121. doi: 10.1007/s12265-009-9154-1.