

CASE REPORT

# Vitamin D Supplementation Replaced Catheter Ablation in a Patient with Frequent Premature Ventricular Contractions

Gabriel Cismaru, Dana Pop, Dumitru Zdrenghea, Radu Rosu

Fifth Department of Internal Medicine, Cardiology–Rehabilitation, “Iuliu Hațieganu” University of Medicine and Pharmacy, Cluj–Napoca, Romania

## ABSTRACT

A high premature ventricular contractions (PVC) burden can disturb the patient’s condition through fatigue during exercise or palpitations. Hence, researchers started to look for treatment options that decrease PVC burden without the side effects of antiarrhythmic drugs, and vitamin D could be a valuable solution and safe alternative to drugs or catheter ablation for high-burden PVCs. We present the case of a 24-year-old patient with high-burden PVC of >25,500/24 hours referred for urgent catheter ablation. Treatment with beta-blockers and calcium blockers did not reduce PVC burden. Under propafenone, there was a slight reduction in the number of PVCs to 21,200/24 hours, therefore the patient was referred for catheter ablation. As there was a vitamin D deficiency of 10.1 ng/mL, an attempt of vitamin D supplementation was done, with increase of vitamin D to 32.1 ng/mL and decrease of PVC burden to 9,600/24 hours. Further dietary supplementation increased 25-OH vitamin D to 50.2 ng/mL and decreased the PVC burden to 119/24 hours. Consequently, catheter ablation was canceled, and the patient remained free of antiarrhythmic drugs.

**Keywords:** vitamin D3, 25-OH vitamin D, premature ventricular contractions, cardiac function, sunlight

## ARTICLE HISTORY

Received: December 7, 2020  
Accepted: March 1, 2021

## CORRESPONDENCE

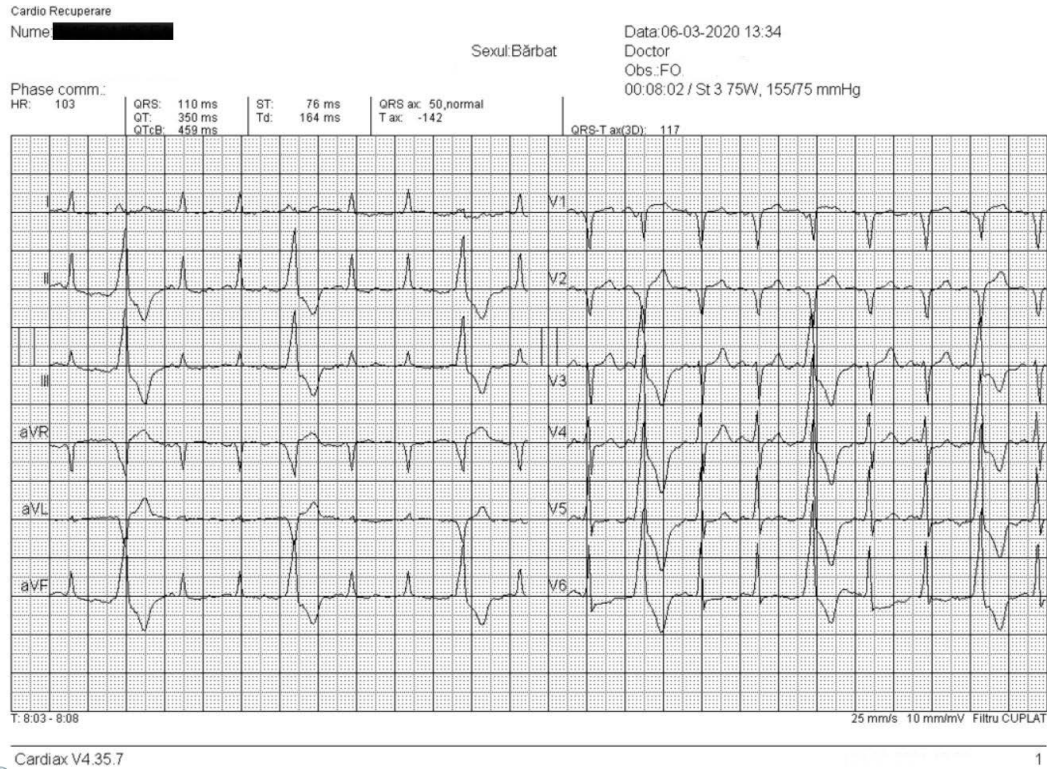
**Gabriel Cismaru**  
Str. Viilor nr. 46–50  
400347 Cluj–Napoca, Romania  
Tel: +40 264 207 021  
E-mail: gabi\_cismaru@yahoo.com

## INTRODUCTION

Vitamin D is a steroid hormone regulating the homeostasis of calcium and bone mineralization. Both hypocalcemia and vitamin D deficiency have unfavorable effects on cardiac function and have implications in the development of coronary artery disease,<sup>1</sup> heart failure,<sup>2</sup> left ventricular hypertrophy,<sup>3</sup> atherosclerosis,<sup>4</sup> and atrial fibrillation.<sup>5</sup>

Premature ventricular contractions (PVCs) are a frequent cause of palpitations and occur in almost 50% of

individuals.<sup>6</sup> PVCs are harmless when they occur in patients without heart disease. However, they can induce arrhythmogenic cardiomyopathy<sup>7</sup> in case of high-burden PVC, or trigger ventricular tachycardia and ventricular fibrillation.<sup>8</sup> Hence, a reduction in PVC burden may result in fewer serious arrhythmic events or arrhythmogenic cardiomyopathies. However, the reduction in PVC burden might be offset by side effects of antiarrhythmic drugs. In the Cardiac Arrhythmic Suppression Trial (CAST), encainide and flecainide reduced the PVC burden but also



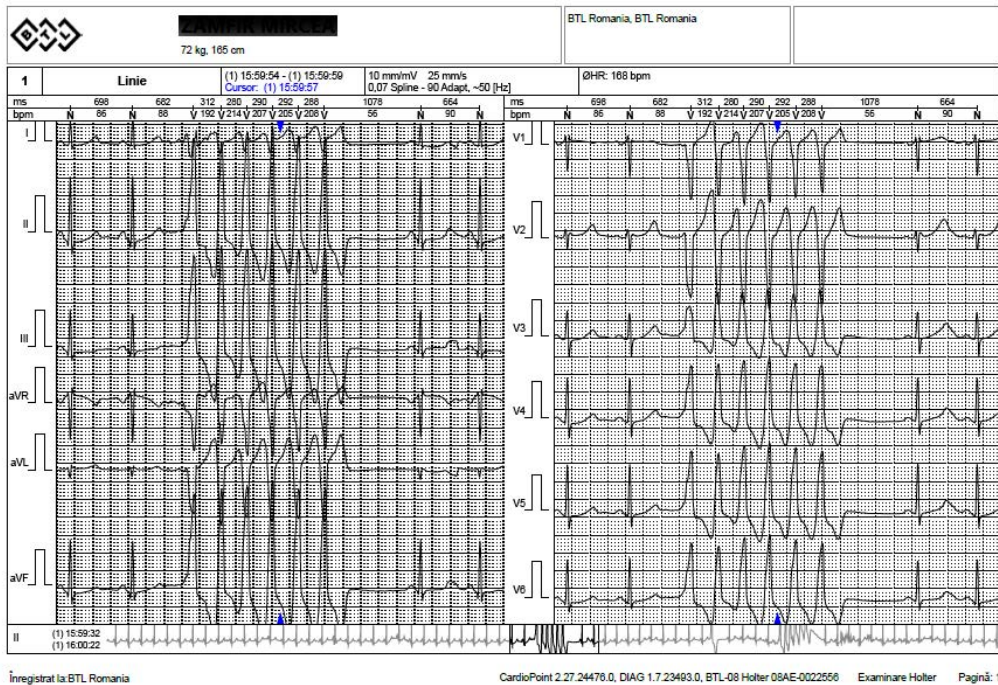
**FIGURE 1.** Twelve-lead ECG shows sinus rhythm with ventricular bigeminism. PVC morphology is: LBBB appearance with inferior axis and precordial transition in lead V3

increased mortality.<sup>9</sup> Hence, researchers started to look for other treatment options that may decrease PVC burden without the side effects of antiarrhythmic drugs. Vitamin D might be a valuable solution and safe alternative to drugs in the treatment of PVCs.

## CASE PRESENTATION

A 24-year-old male patient was referred to our cardiology department for urgent catheter ablation of high-burden PVC. He presented with intermittent palpitations and mild exertional dyspnea. The physical examination showed normal findings: blood pressure of 120/70 mmHg, heart rate of 72 bpm, with no signs of left or right heart failure. Blood test showed normal values of complete blood count, biochemistry, and coagulation, except a low value of 25-OH vitamin D: 10.1 ng/mL (normal values >30 ng/mL). The ECG showed frequent PVCs with a left bundle branch block morphology and inferior axis, precordial transition in V4. Figure 1 shows PVC morphology, suggestive of right ventricular outflow tract (RVOT) origin. The echocardiographic examination did not reveal significant valve disease, the heart chamber dimensions were normal, and there was no sign of arrhythmogenic cardiomyopathy, the left ventricular ejection fraction being 60%. At

this time, the patient was diagnosed with RVOT PVCs and insufficient vitamin D. The 24-hour Holter ECG showed a high burden of premature contractions: 25,500 PVCs/24 hours and episodes of non-sustained ventricular tachycardia (Figure 2). Beta-blockers and calcium-channel blockers were ineffective in reducing the PVC burden, therefore the patient was started on propafenone 3 × 150 mg and presented a reduction in the PVC burden to 21,200 after 2 weeks (17% relative reduction). As the palpitations persisted with exertional dyspnea, he was referred for catheter ablation. The laboratory tests showed insufficient levels of 25-OH vitamin D. Therefore, we decided to attempt vitamin D supplementation for 1 month before catheter ablation. After cessation of propafenone treatment, the patient was started with 2,000 U of vitamin D<sub>3</sub> daily, without the use of any antiarrhythmic drugs. During the 2 weeks of follow-up, the patient was free of palpitations, thus he continued treatment for 2 more weeks, and 25-OH vitamin D levels had increased to 16.9 ng/mL. After 2 months of daily vitamin D supplementation, the serum level of 25-OH vitamin D level had increased to 24.7 ng/mL. At this point, the PVC burden decreased to 11,800/24 hours (a 53% relative reduction). At the end of 5 months of vitamin D supplementation, the level of 25-OH vitamin D had increased to 50.2 ng/mL with a decrease of PVC



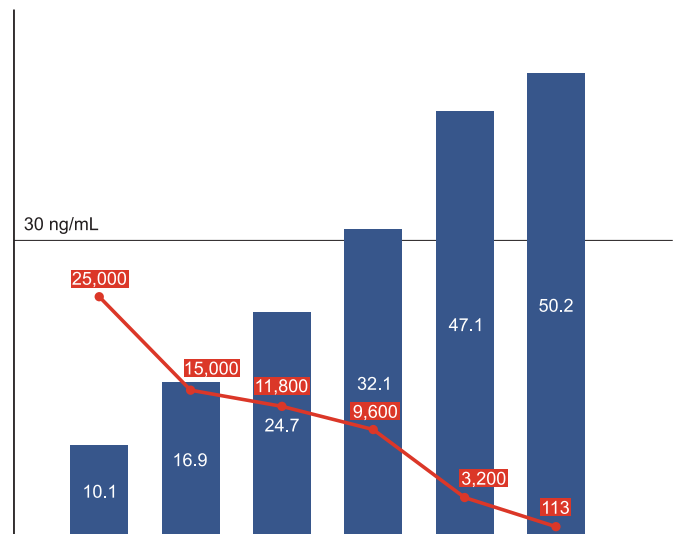
**FIGURE 2.** Holter ECG shows multiple PVCs with non-sustained episodes of monomorphic ventricular tachycardia. PVC burden was 25,500/24 hours

burden to 119/24 hours (a 99% relative reduction). Figure 3 shows the reduction of PVC burden associated with the increase of 25-OH vitamin D levels. Therefore, the catheter ablation procedure was canceled, and the patient was prescribed only vitamin D supplementation without antiarrhythmic drugs. We recommended sunlight exposure during the summer season and vitamin D supplementation during the winter season (2,000 U/day). The patient agreed with the publication of his case, without images of parts of his body that could confirm his identity. The Ethics Committee of the Cardiology-Rehabilitation Hospital of Cluj-Napoca, Romania, had approved the publication of this report.

## DISCUSSIONS

Our case report demonstrates that vitamin D deficiency can be responsible for high burden of PVC, and vitamin D supplementation can significantly lower this burden. RVOT PVCs have a left bundle branch block, inferior axis morphology displaying a late precordial transition in lead V<sub>4</sub>. In contrast, LVOT PVCs have an inferior axis but with an early precordial transition in V<sub>2</sub>. Both RVOT and LVOT PVCs are “benign PVCs” with a triggered activity mechanism caused by delayed after-depolarizations via cAMP

and intracellular calcium overload. Medication that can directly inhibit arrhythmia pathways are calcium-channel blockers, beta-blockers, and adenosine. However, vitamin D supplementation might be a good option for this category of patients.<sup>10</sup>



**FIGURE 3.** Diagram showing decrease in the number of PVCs (red line) concomitant with an increase in the plasmatic concentration of 25-OH vitamin D (blue bars)



Vitamin D deficiency, which is very prevalent in Europe, might have an important role in PVC genesis. Vitamin D<sub>3</sub> is generated in the skin under the influence of sunlight. It has no significant biological activity, but after metabolism to 25-OH vitamin D and further to 1,25-OH vitamin D, it stimulates the absorption of calcium, phosphate, and magnesium from the intestine. The presence of vitamin D receptors in several types of cells, including cardiac myocytes, have demonstrated widespread biological effects beyond bone metabolism. In 1985, a cardiac receptor for the active metabolite of vitamin D was identified in the myocardial cell: the 1,25 dihydroxy-vitamin D<sub>3</sub> receptor. The presence of vitamin D receptors together with the vitamin D<sub>3</sub>-dependent calcium-binding protein regulate the action of vitamin D and calcium on cardiac metabolism both in hypocalcemic and normocalcemic states.<sup>11</sup>

The prevalence of vitamin D deficiency varies according to its lower limit of <20 or <30 ng/mL. There is no international consensus on optimal serum values of vitamin D. Experts agree that the level needed for a good bone health should be more than 20 ng/mL.<sup>12</sup> Conversely, the International Osteoporosis Foundation and the Endocrine Society propose values higher than 30 ng/mL. However, experts agree that there is no cut-off value of plasma levels of vitamin D in relation to extra-skeletal health. Our report shows that 30 ng/mL might be insufficient to prevent PVCs, and 50 ng/mL might be a better target for patients presenting PVCs. We do not think that a higher value >50 ng/mL can bring a more relevant benefit, but this should be tested and proven in large clinical studies.

In Romania, due to its latitude (48°15'N to 43°40'N), there is a seasonal variation of vitamin D levels: it increases from April to September and decreases from October to March.<sup>13</sup> Our patient had presented with vitamin D deficiency, which might be variable according to different seasons of the year. The first value of 25-OH vitamin D of 10.1 ng/mL was without any vitamin D supplementation; the following values were detected after the administration of vitamin D supplements, the highest level being 50.2 ng/mL. It was demonstrated that Caucasians, after body exposure to sunlight for 10 to 15 minutes, can generate approximately 20,000 U of vitamin D. Therefore, our patient was advised to acquire sunlight exposure during summer months and to take vitamin D supplements during the winter. We used 2,000 U/day vitamin D supplementation to increase the levels of 25-OH vitamin D. A better option for a faster effect might be 5,000 U/day. We preferred the low dose in order to prevent vitamin D toxicity, which is however a rare finding and needs serum levels higher than >150 ng/mL.

In the presented case, the level of ionized calcium was normal, even though vitamin D was deficient. Therefore, frequent PVCs cannot be attributable to hypocalcemia, but rather to low levels of vitamin D. Many studies have shown that even if there is a clear relationship between vitamin D, parathormone, and calcium homeostasis, there is a weak correlation between vitamin D levels and ionized calcium levels.<sup>14–17</sup> When vitamin D is reduced, active calcium absorption is also reduced, in spite of normal ionized calcium levels. Therefore, calcium-induced calcium release from intracellular stores could also be reduced.

In general, the success rate of radiofrequency ablation in PVCs originating in the RVOT is high. In most studies, a success rate of >80%<sup>18</sup> has been reported with a low long-term recurrence rate of <5%.<sup>19</sup> Catheter ablation is generally used when the patient is symptomatic, develops arrhythmic cardiomyopathy, or is at risk of developing arrhythmic cardiomyopathy (PVC burden of >20–24%).<sup>20</sup> The change in PVC burden observed in our patient cannot be attributed to spontaneous variability, defined as less than 20% reduction in PVCs. A positive response to treatment in patients with PVCs can be defined as a reduction of PVC burden by more than 70%.<sup>21</sup> In our patient, the reduction percentage was 61.6% when 25-OH vitamin D had reached 30 ng/mL and more than 99% with an increase to 50 ng/mL. Therefore, we believe that vitamin D supplementation is effective in patients with high-number PVCs, without the need of antiarrhythmic drugs or catheter ablation, and the optimal level of 25-OH vitamin D is close to 50 ng/mL.

## CONCLUSIONS

Our report demonstrates that vitamin D deficiency can be a cause of high-burden PVCs. Vitamin D supplementation is an easy and effective therapeutic option, with significant reduction in PVC burden. Furthermore, antiarrhythmic drugs and catheter ablation might be avoided in this scenario.

## CONFLICT OF INTEREST

Nothing to declare.

## REFERENCES

1. Rocchiccioli S, Andreassi MG, Cecchetti A, Carpeggiani C, L'Abbate A, Citti L. Correlation between vitamin D binding protein expression and angiographic-proven coronary artery disease. *Coron Artery Dis.* 2012;23:426–431. doi: 10.1097/MCA.0b013e328358781c.

2. Patel R, Rizvi AA. Vitamin D deficiency in patients with congestive heart failure: mechanisms, manifestations, and management. *South Med J.* 2011;104:325-330. doi: 10.1097/SMJ.0b013e318213cf6b.
3. O'Connell TD, Berry JE, Jarvis AK, Somerman MJ, Simpson RU. 1,25-Dihydroxyvitamin D<sub>3</sub> regulation of cardiac myocyte proliferation and hypertrophy. *Am J Physiol.* 1997;272:H1751-H1758. doi: 10.1152/ajpheart.1997.272.4.H1751.
4. Surdu AM, Pînzariu O, Ciobanu DM, et al. Vitamin D and Its Role in the Lipid Metabolism and the Development of Atherosclerosis. *Biomedicines.* 2021;9:172. doi: 10.3390/biomedicines9020172.
5. Demir M, Uyan U, Melek M. The effects of vitamin D deficiency on atrial fibrillation. *Clin Appl Thromb Hemost.* 2014;20:98-103. doi: 10.1177/1076029612453762.
6. Barret PA, Peter CT, Swan HJ, Singh BN, Mandel WJ. The frequency and prognostic significance of electrocardiographic abnormalities in clinically normal individuals. *Prog Cardiovasc Dis.* 1981;23:299-319. doi: 10.1016/0033-0620(81)90018-9.
7. Maggioni AP, Zuanetti G, Franzosi MG, et al. Prevalence and prognostic significance of ventricular arrhythmias after acute myocardial infarction in the fibrinolytic era. GISSI-2 results. *Circulation.* 1993;87:312-322. doi: 10.1161/01.cir.87.2.312.
8. Jimenez RA, Myerburg RJ. Sudden cardiac death. Magnitude of the problem, substrate/trigger interaction, and populations at high risk. *Cardiol Clin.* 1993;11:1-9.
9. The Cardiac Arrhythmia Suppression Trial (CAST) Investigators. Preliminary report: effect of encainide and flecainide on mortality in a randomized trial of arrhythmia suppression after myocardial infarction. *N Engl J Med.* 1989;321:406-412. doi: 10.1056/NEJM198908103210629.
10. Cismaru G, Gurzau D, Fringu F, Martis A, Caloian B, Comsa H. Vitamin D supplementation with Cardiac Rehabilitation reduces the number of RVOT Premature Ventricular Contractions. *Balneo Research Journal.* 2020;11:566-568.
11. Weishaar RE, Simpson RU. Involvement of vitamin D<sub>3</sub> with cardiovascular function. II. Direct and indirect effects. *Am J Physiol.* 1987;253:E675-E683. doi: 10.1152/ajpendo.1987.253.6.E675.
12. Ross AC, Manson JE, Abrams SA, et al. The 2011 report on dietary reference intakes for calcium and vitamin D from the Institute of Medicine: what clinicians need to know. *J Clin Endocrinol Metab.* 2011;96:53-58. doi: 10.1210/jc.2010-2704.
13. Chirita-Emandi A, Socolov D, Haivas C, et al. Vitamin D status: a different story in the very young versus the very old Romanian patients. *PLoS One.* 2015;10:1-14. doi: 10.1371/journal.pone.0128010.
14. Steingrimsdottir L, Gunnarsson O, Indridason OS et al. Relationship between serum parathyroid hormone levels, vitamin D sufficiency and calcium intake. *JAMA.* 2005;294:2336-2341. doi: 10.1001/jama.294.18.2336.
15. Huss L, Butt S, Borquist S et al. Serum levels of vitamin D, parathyroid hormone and calcium in relation to survival following breast cancer. *Cancer Causes Control.* 2014;25:1131-1140. doi: 10.1007/s10552-014-0413-3.
16. Vierucci F, Pistoia MD, Fanos M, et al. Vitamin D status and predictors of hypovitaminosis D in Italian children and adolescents: a cross-sectional study. *Eur J Pediatr.* 1-11. doi: 10.1007/s00431-013-2119-z.
17. Azab SF, Saleh SH, Elsaheed WF, et al. Vitamin D status in diabetic Egyptian children and adolescents: a case-control study. *Italian Journal of Pediatrics.* 2013;39:73. doi: 10.1186/1824-7288-39-73.
18. Coggins DL, Lee RJ, Sweeney J, et al. Radiofrequency catheter ablation as a cure for idiopathic tachycardia of both left and right ventricular origin. *J Am Coll Cardiol.* 1994;23:1333-41. doi: 10.1016/0735-1097(94)90375-1.
19. Krittayaphong R, Sriratanasathavorn C, Dumavibhat C, et al. Electrocardiographic predictors of long-term outcomes after radiofrequency ablation in patients with right-ventricular outflow tract tachycardia. *Europace.* 2006;8:601-6. doi: 10.1093/europace/eul067.
20. Baman TS, Lange DC, Ilg KJ, et al. Relationship between burden of premature ventricular complexes and left ventricular function. *Heart Rhythm.* 2010; 7:865-9. doi: 10.1016/j.hrthm.2010.03.036.
21. Gudbjarnarson S. The ESVEM Investigators. Determinants of predicted efficacy of antiarrhythmic drugs in the electrophysiologic versus electrocardiographic monitoring trial. *Circulation.* 1993;87:323-329.