

CASE REPORT

Ventricular Dysfunction in the Case of the Sever Fetal Aortic Stenosis – the Role of Speckle-tracking

Liliana Gozar^{1,2}, Daniela Toma^{1,2}, Amalia Făgărășan^{1,2}, Dorottya Miklósi¹, Rodica Togănel^{1,2}

¹ “George Emil Palade” University of Medicine, Pharmacy, Science and Technology, Târgu Mureș, Romania

² Emergency Institute of Cardiovascular Diseases and Transplantation, Târgu Mureș, Romania

ABSTRACT

Congenital aortic stenosis (AS) occurs in around 0.2–0.5% of newborns, and its clinical severity is quite variable. Some of the newborns with AS require urgent medical care: prostaglandin infusion, balloon aortic valvuloplasty, or surgical intervention. Despite having a severe clinical evolution in neonates, the prenatal diagnosis of congenital AS is quite low. We present the case of a fetus with critical AS, who had been prenatally diagnosed at 35 weeks of gestation, via fetal cardiac ultrasound. The echocardiographic parameters revealed a severely depressed left ventricular systolic function, with dilated chambers, and a severe aortic stenosis. Offline speckle-tracking analysis was performed in order to aid in deciding the optimal methods and timing of delivery. Left ventricular analysis revealed a severely impaired global longitudinal strain of 2.1%, left ventricular ejection fraction 18.4%, increased LV volumes, while the right ventricular function was only mildly depressed. Therefore, the decision was to delay the premature delivery, and the fetus was born at a gestational age of 38 weeks, in a hospital with a neonatal cardiovascular surgery department. The patient had undergone surgical repair of the cardiac anomaly at 3 days after birth.

Keywords: congenital aortic stenosis, speckle-tracking, left ventricular dysfunction

ARTICLE HISTORY

Received: October 16, 2019

Accepted: November 23, 2019

CORRESPONDENCE

Daniela Toma

Str. Gheorghe Marinescu nr. 38
540139 Târgu Mureș, Romania
Tel: +40 745 652 688

E-mail: tomadaniela94@yahoo.com

INTRODUCTION

Bicuspid aortic valve (BAV) is the most frequent congenital heart defect, with a prevalence of 4.6 in 1,000 live births, being more frequent in males. Most patients with BAV are asymptomatic, but some of them have aortic stenosis (AS), aortic regurgitation, or dilation of the ascending aorta.¹ Congenital AS occurs in around 0.2–0.5% of newborns, and its clinical severity is quite variable. Some of the newborns with AS require urgent medical care: prostaglandin infusion, balloon aortic valvuloplasty, or surgical

intervention. AS is an obstructive lesion of the left heart, thus it can associate different degrees of mitral stenosis, hypoplasia of the aorta or left ventricle. Although it is a condition with an extremely severe evolution in the neonate, the percentage of cases diagnosed prenatally with this pathology is quite low, according to recent studies.^{2,3}

CASE PRESENTATION

The purpose of this paper is to present the case of a pregnant patient, at the gestational age of 35 weeks, with a

Liliana Gozar: Str. Gheorghe Marinescu nr. 38, 540139 Târgu Mureș, Romania. Tel: +40 265 215 551, E-mail: lili_gozar@yahoo.com

Amalia Făgărășan: Str. Gheorghe Marinescu nr. 38, 540139 Târgu Mureș, Romania. Tel: +40 265 215 551, E-mail: amalia_fagarasan@yahoo.com

Dorottya Miklósi: Str. Gheorghe Marinescu nr. 38, 540139 Târgu Mureș, Romania. Tel: +40 265 215 551, E-mail: annadorka@yahoo.com

Rodica Togănel: Str. Gheorghe Marinescu nr. 38, 540139 Târgu Mureș, Romania. Tel: +40 265 215 551, E-mail: rodicatoganel@yahoo.com

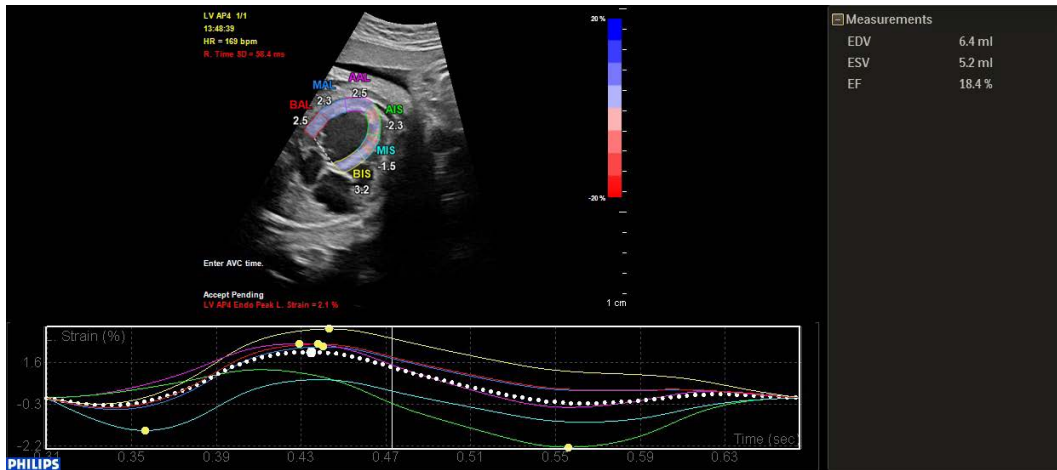


FIGURE 1. Apical four-chamber view. Left ventricle: traced myocardial wall and interventricular septum for myocardial deformation analysis (strain) using 2D speckle-tracking echocardiography. Curves for left ventricle longitudinal peak systolic strain (%) for six segments and global strain (%). BAL – basal lateral; MAL – middle lateral; AAL – apical lateral; AIS – apical septal; MIS – middle septal; BIS – basal septal

proper follow-up during pregnancy. The patient was referred to the pediatric cardiology clinic for fetal echocardiography, where the fetus was diagnosed with a congenital heart disease.

The echocardiographic examination, performed with an Epiq 7 Cardiology ultrasound System (Phillips Healthcare, Amsterdam, Netherlands), revealed a fetal heart with normal atrioventricular and ventriculoarterial connections, but with a modified aspect when visualized from the four-chamber view: the left ventricle was dilated, having a severely altered contractile function; there were areas of endomyocardial fibroelastosis at the level of the lateral wall and below the mitral valvular apparatus; the

left atrium was dilated, while the right-sided cavities were compressed by the left cardiac chambers. In five-chamber view showing the aorta, the aortic valve was found to have a hyperechogenic aspect and limited mobility. Upon the examination of the heart with Doppler color flow, a severe mitral regurgitation was confirmed, with minimal antero-grad flow in the ascending aorta and a bidirectional flow through the patent foramen ovale. The pulsed Doppler mode confirmed the passage of the blood flow through the aortic valve, with an increased velocity, and at the site of the mitral valve the flow was monophasic. From the parasagittal view an aortic coarctation was excluded and a large persistent ductus arteriosus was visualized. Based

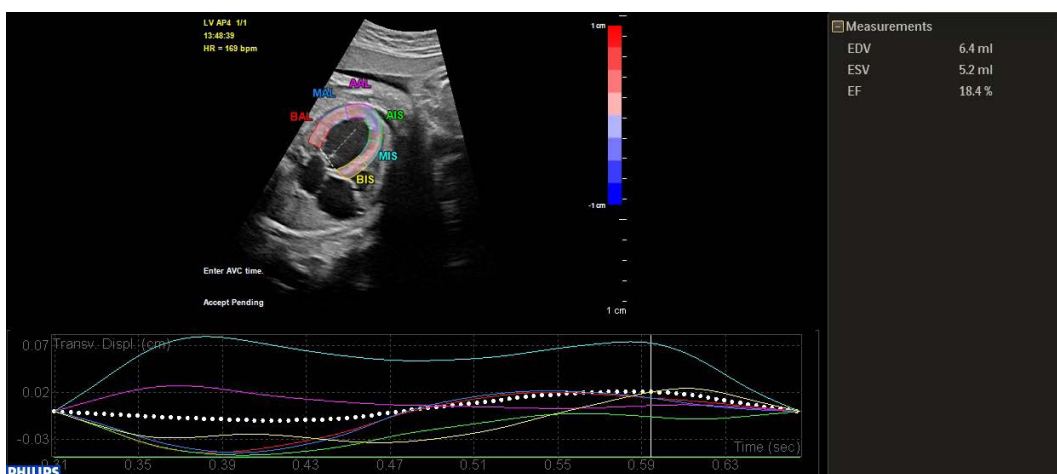


FIGURE 2. Apical four-chamber view. Left ventricle: traced myocardial wall and interventricular septum for myocardial deformation analysis (strain) using 2D speckle-tracking echocardiography. Curves for left ventricle transverse peak systolic strain (%) for six segments. BAL – basal lateral; MAL – middle lateral; AAL – apical lateral; AIS – apical septal; MIS – middle septal; BIS – basal septal

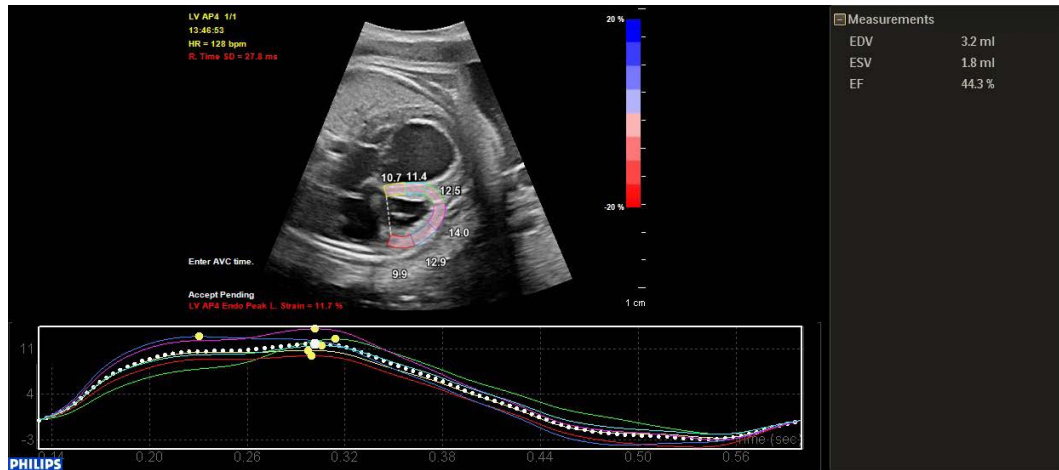


FIGURE 3. Apical four-chamber view. Right ventricle: traced myocardial wall and interventricular septum for myocardial deformation analysis (strain) using 2D speckle-tracking echocardiography. Curves for right ventricle longitudinal peak systolic strain (%) for six segments and global strain (%)

on these images, the diagnosis of a severe valvular aortic stenosis was established.

The first question that arose in this clinical setting, considering the gestational age, was related to the moment of birth; more precisely, to correctly establish the recommendation of a premature cesarean section, a triggered premature vaginal birth, or the continuation of pregnancy and birth as close as possible to term, the last option offering the highest chance of a favorable postnatal evolution.

In the attempt to evaluate the hemodynamic status of the fetus as accurately as possible, we performed an offline two-dimensional speckle-tracking analysis with the use of Qlab version 13 software (Philips QLAB Ultrasound Cardiac Analysis, 2014 Koninklijke Philips N.V.). For this, we used a high frame rate image of the 4-chamber view that fills most of the screen. We started by observing the mitral valve closure in order to identify end-diastole in the fetal heart. The endocardial and epicardial borders were automatically tracked using the aCMQ (Automated Cardiac Motion Quantification) tool of the Qlab13 software. We reviewed the cardiac cycle to see whether the contour was correctly tracked. The speckle-tracking analysis revealed a severely depressed left ventricular function with left chamber dilation as illustrated via a global longitudinal strain of 2.1%, with a left ventricular ejection fraction of 18.4%, and increased LV volumes (end-diastolic volume of 6.4 mL and end-systolic volume of 5.2 mL). The right ventricular analysis illustrated a moderately depressed systolic function with an ejection fraction of 44.3% and an impaired global longitudinal strain of 11.7%.

Following the analysis of ventricular function, we objectified and quantified the impairment of systolic function. We decided that in the condition of fetal circulation, a left ventricle ejection fraction of 18% and a right ventricle ejection fraction of 44.3% should permit the delay of premature birth and the attempt to continue with the pregnancy until term. The birth occurred at the gestational age of 38 weeks in the Kepler University Clinic Linz, where neonatal cardiovascular surgical therapy was available. The Ross-Konno procedure was carried out on the baby three days after birth.

DISCUSSION

Critical AS represents a cardio-surgical emergency in the neonatal period. According to a multicenter, retrospective study recently published by Freud *et al.*, the rate of prenatal diagnosis among neonates with critical AS was very low and did not improve over the study period of 13 years.⁴ In contrast, hypoplastic left heart syndrome benefits from an increased rate of intrauterine detection. It is well known that severe AS in the mid-gestation fetus can evolve to hypoplastic left heart syndrome. The echocardiographic signs that can foretell the progression to hypoplastic left heart syndrome, despite of a left ventricle of normal dimensions, are the following: reverse flow in the transverse aortic arch, left to right flow through the foramen ovale, and monophasic mitral flow.⁴ These cases have a clear indication for balloon aortic valvuloplasty until the gestational age of 24 weeks. In the case presented in this article, the gestational age of 35 weeks no longer allowed intrauterine balloon valvuloplasty. Being

a severe lesion, with an extremely dilated left ventricle and altered contractile function, it was difficult to decide upon the continuation of pregnancy until term. We compared our results to those found in studies published to date in the field. We observed that our fetus had significantly reduced systolic and diastolic strain rates in the left ventricle, but had acceptable values for the right ventricle.^{5–7}

The evaluation of systolic function using 2D speckle-tracking analysis was useful in this case, being the only available method for quantifying the severity of left and right ventricular dysfunction. Several studies concerning speckle-tracking analysis for the fetal heart conclude that this method of evaluating cardiac function can be used in the intrauterine period. In healthy fetuses, global longitudinal peak systolic velocities increase during gestation, and significant regional cardiac dysfunction may occur in the fetuses with congenital heart disease.⁸ Most studies conclude that further investigation is required before this new technique can be implemented in routine clinical practice.⁸

CONCLUSION

The presented case is a clinical example that supports the importance of 2D speckle tracking for the evaluation of myocardial function in the fetal heart. Myocardial strain of the right and left ventricle, assessed in the fetal heart, may aid the therapeutic decision-making process in case of congenital heart disease.

CONFLICT OF INTEREST

Nothing to declare.

REFERENCES

1. Tutar E, Ekici F, Atalay S, Nacar N. The prevalence of bicuspid aortic valve in newborns by echocardiographic screening. *Am Heart J.* 2005;150:513–515. doi: 10.1016/j.ahj.2004.10.036.
2. Graupner O, Enzensberger C, Axt-Fliedner R. New Aspects in the Diagnosis and Therapy of Fetal Hypoplastic Left Heart Syndrome. *Geburtshilfe Frauenheilkd.* 2019;79:863–872. doi: 10.1055/a-0828-7968.
3. Freud LR, Moon-Grady A, Escobar-Diaz MC, et al. Low rate of prenatal diagnosis among neonates with critical aortic stenosis: insight into the natural history in utero. *Ultrasound Obstet Gynecol.* 2015;45:326–332. doi: 10.1002/uog.14667.
4. Freud LR, McElhinney DB, Marshall AC, et al. Fetal Aortic Valvuloplasty for Evolving Hypoplastic Left Heart Syndrome: Postnatal Outcomes of the First 100 Patients. *Circulation.* 2014;130:638–645. doi: 10.1161/CIRCULATIONAHA.114.009032.
5. Ishii T, McElhinney DB, Harrild DM, et al. Circumferential and longitudinal ventricular strain in the normal human fetus. *J Am Soc Echocardiogr.* 2012;25:105–111. doi:10.1016/j.echo.2011.09.016.
6. DeVore GR, Cuneo B, Klas B, Satou G, Sklansky M. Comprehensive Evaluation of Fetal Cardiac Ventricular Widths and Ratios Using a 24-Segment Speckle Tracking Technique. *J Ultrasound Med.* 2019;38:1039–1047. doi: 10.1002/jum.14792.
7. Forsey J, Friedberg MK, Mertens L. Speckle Tracking Echocardiography in Pediatric and Congenital Heart Disease. *Echocardiography.* 2013;30:447–459. doi: 10.1111/echo.12131.
8. Willruth AM, Geipel AK, Fimmers R, Gembruch UG. Assessment of right ventricular global and regional longitudinal peak systolic strain, strain rate and velocity in healthy fetuses and impact of gestation age using a novel speckle/feature-tracking based algorithm. *Ultrasound Obstet Gynecol.* 2011;37:143–149. doi:10.1002/uog.7719.