

## EDITORIAL

# A New Definition of Acute Myocardial Infarction – Changing Perspectives in Acute Cardiac Care

Imre Benedek

University of Medicine, Pharmacy, Science and Technology, Tîrgu Mureş, Romania

In 2018, the European Society of Cardiology (ESC) released two new recommendations with a major impact on acute cardiac care: the 2018 ESC/EACTS guidelines on myocardial revascularization, and the fourth universal definition of myocardial infarction (MI).<sup>1,2</sup> Both guidelines are extremely valuable for all clinicians involved in acute cardiovascular care, providing new evidence-based recommendations for the optimal management of acute MI.

Among the new concepts present in the fourth definition of MI, three will certainly have a major impact in daily practice: the clear differentiation between myocardial infarction and myocardial injury, the concept of electrical remodeling, and the use of cardiac magnetic resonance (CMR) in the acute phase of MI.

## FROM MYOCARDIAL INJURY TO MYOCARDIAL INFARCTION

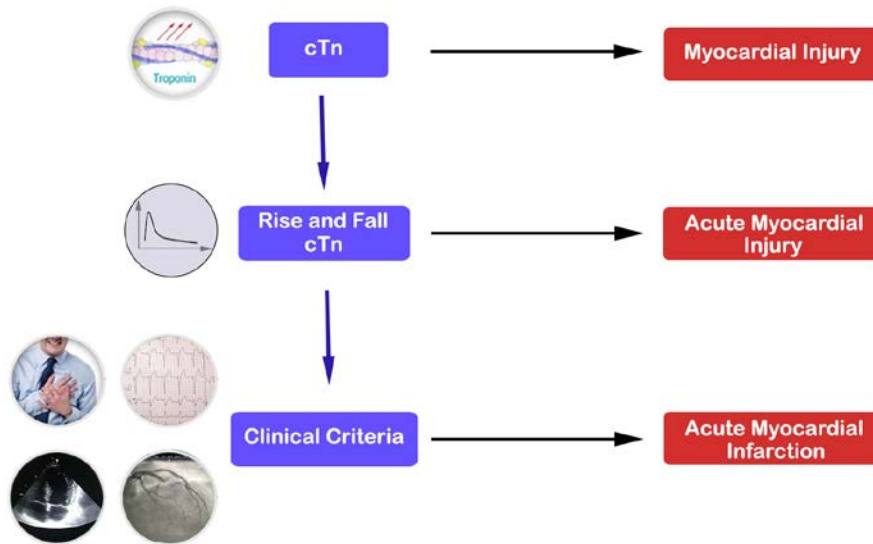
The fourth definition of MI introduces the concept of myocardial injury, as a distinct pathophysiologic process characterized by elevated levels of cardiac troponin (cTn), with at least one value above the 99th percentile.<sup>1</sup> Only when the elevation of cTn presents a rise and/or fall pattern, this myocardial injury can be considered as an acute condition, and a final diagnosis of acute MI can be established only when the acute myocardial injury is associated with at least one of the classical clinical criteria (symptoms, ECG changes, imaging evidence of viability loss, new wall motion abnormality, or intracoronary thrombus).<sup>1</sup> In order to detect the rise and/or fall pattern of cTn elevation specific for acute myocardial injury,

blood sampling should occur at least twice: the first time at the moment of the first assessment, and the second one 3–6 hours later.<sup>1</sup> Figure 1 illustrates the difference between myocardial injury, acute myocardial injury, and myocardial infarction.

Differentiation of MI from myocardial injury has a significant clinical impact, as many patients presenting to the emergency room have myocardial injury caused by other conditions such as renal insufficiency, congestive heart failure, pulmonary embolism etc.<sup>3</sup> Especially in the case of non-ST-elevation MI, when ECG changes might be less specific, distinction of an acute coronary event from non-ischemic myocardial injury could be life-saving.

## ELECTRICAL REMODELING – A NEW CONCEPT IN ACUTE CARDIAC CARE

A frequent scenario in the emergency room is represented by a patient with atrial fibrillation (AF) and rapid heart rate, who develops new ST-T changes (ST-segment depression or T-wave inversion) on surface ECG, in the absence of any significant coronary artery stenosis. This phenomenon is partially explained in the 4th definition as a result of the so-called “cardiac memory” related to electrical remodeling, a process resulting from transient conduction disturbances associated with a high heart rate.<sup>1</sup> Therefore, according to this new definition, a patient with new-onset AF, new ST-T changes, and increase in cTn levels should not be automatically diagnosed as having an acute MI, in the absence of other clinical evidence of myocardial ischemia.<sup>1</sup>



**FIGURE 1.** The difference between myocardial injury, acute myocardial injury, and myocardial infarction according to the new universal definition of myocardial infarction

## CARDIAC MAGNETIC RESONANCE IN THE ACUTE PHASE OF MYOCARDIAL INFARCTION

Another major development in the new recommendations is related to the use of CMR in acute settings, for two main indications: (1) to assess the infarct size, the extent of myocardium at risk, and the degree of microvascular obstruction or intramyocardial hemorrhage; and (2) to identify the etiology of myocardial injury in unclear cases.<sup>1</sup> Acute MI with normal coronary arteries (MINOCA) has been recently recognized as a new entity in acute cardiac care, being recorded in approximately 5–15% of patients with acute coronary syndromes.<sup>3,4</sup> In these cases with unknown etiology, CMR may have a significant contribution to elucidate a diagnosis of myocarditis or MI with spontaneous recanalization, being recommended as a first step examination after angiographic exclusion of any significant coronary artery obstruction. Another promising application of CMR in acute MI is for the detection of myocardial scarring in patients with late presentation, case in which CMR is able to establish the diagnosis of ischemic myocardial necrosis.<sup>1</sup>

## MYOCARDIAL REVASCUARIZATION IN ACUTE MYOCARDIAL INFARCTION AND CRITICAL CONDITIONS – NEW RECOMMENDATIONS

In patients with cardiogenic shock and multiple vessel disease, the recently published ESC/EACTS guidelines on myocardial revascularization clearly contraindicate com-

plete revascularization and recommend primary percutaneous coronary revascularization (PCI) of the culprit lesion only, followed by staged procedures for the other stenoses.<sup>2</sup> This significant change in recommendations substantially modifies the management strategy of complex acute MI cases, being supported by the results of several recent trials. The CULPRIT-SHOCK trial (Culprit Lesion Only PCI versus Multivessel PCI in Cardiogenic Shock, NCT:01927549), demonstrated that in patients with multivessel disease, AMI, and cardiogenic shock, a strategy consisting in primary PCI of the culprit lesion only is superior to complete revascularization of all coronary lesions in emergency.<sup>5</sup> The results of the CULPRIT-SHOCK trial led to the current recommendation to avoid multivessel PCI in the case of cardiogenic shock complicating acute MI (class III indication).

At the same time, according to 2018 guidelines, the recommendation to perform immediate coronary angiography and revascularization, when indicated, in survivors of out-of-hospital cardiac arrest, if their ECG recording is highly suggestive of STEMI, has been updated from class IIa to class I indication.<sup>2</sup>

In conclusion, the new European recommendations released by the ESC in 2018 open new perspectives in acute cardiac care, providing more evidence-based support for clinical decision in complex cases. The concepts of myocardial injury, AF-associated electrical remodeling, and CMR in the acute phase represent modern approaches useful for a better management of MI, while indications

related to primary PCI in the case of cardiogenic shock complicating acute MI have been reconsidered in favor of infarct-related only PCI. At the same time, the new European recommendations emphasize more clearly the need for immediate coronary angiography in patients with resuscitated out-of-hospital cardiac arrest and ischemic changes on surface ECG.

## CONFLICT OF INTEREST

Nothing to declare.

## REFERENCES

1. Thygesen K, Alpert JS, Jaffe A, et al. Fourth universal definition of myocardial infarction. *Eur Heart J.* 2018;00:1-33. doi: 10.1093/eurheartj/ehy462.
2. Neumann FJ, Sousa-Uva M, Ahlsson A, et al. The Task Force on myocardial revascularization of the European Society of Cardiology (ESC) and European Association for Cardio-Thoracic Surgery (EACTS). 2018 ESC/EACTS guidelines on myocardial revascularization. *Eur Heart J.* 2018;00:1-96. doi: 10.1093/eurheartj/ehy394.
3. Baine KR, Welsh RC, Alemayehu W, et al. Population-level incidence and outcomes of myocardial infarction with non-obstructive coronary arteries (MINOCA): Insights from the Alberta contemporary acute coronary syndrome patients invasive treatment strategies (COAPT) study. *Int J Cardiol.* 2018;264:12-17. doi: 10.1016/j.ijcard.2018.04.004.
4. Ibanez B, James S, Agewall S, et al. 2017 ESC Guidelines for the management of acute myocardial infarction in patients presenting with ST-segment elevation: The Task Force for the management of acute myocardial infarction in patients presenting with ST-segment elevation of the European Society of Cardiology (ESC). *Eur Heart J.* 2018;39:119-177. doi: 10.1093/eurheartj/ehx393.
5. Thiele H, Akin I, Sandri M, et al. PCI Strategies in Patients with Acute Myocardial Infarction and Cardiogenic Shock. *N Engl J Med.* 2017;377:2419-2432. doi: 10.1056/NEJMoa1710261.