

REVIEW

Gastroenterological Perspectives on Acute Cardiac Care — the Management of Patients with Implanted Coronary Stents Following an Acute Coronary Syndrome

Anca Negovan¹, András Mester², Dan Dumitraşcu³

¹ Clinic of Internal Medicine II, University of Medicine and Pharmacy, Tîrgu Mureş, Romania

² Clinic of Cardiology, University of Medicine and Pharmacy, Tîrgu Mureş, Romania

³ Clinic of Gastroenterology, “Iuliu Haţieganu” University of Medicine and Pharmacy, Cluj-Napoca, Romania

ABSTRACT

Cardiovascular and digestive diseases frequently share the same risk factors such as obesity, unhealthy diet, or several social behaviors, and the increasing prevalence of patients with overlapped cardiovascular and digestive symptoms is a challenging problem in the daily practice. Patients with gastro-esophageal reflux disease can exhibit various forms of chest pain that can be very similar to angina. Furthermore, antithrombotic therapies used for preventive or curative purposes in patients with cardiovascular diseases are frequently associated with gastrointestinal side effects including bleeding. At the same time, in patients with coronary stents presenting to the emergency department with chest pain, angina triggered by stent thrombosis or restenosis should be differentiated from angina-like symptoms caused by a gastrointestinal disease. The aim of this review was to present the complex inter-relation between gastroesophageal diseases and angina in patients on dual antiplatelet therapy following an acute coronary syndrome, with a particular emphasis on the role of anemia resulting from occult or manifest gastrointestinal bleeding, as a precipitating factor for triggering or aggravating angina.

Keywords: dual antiplatelet therapy, gastrointestinal bleeding, recurrent angina

ARTICLE HISTORY

Received: December 15, 2017

Accepted: January 25, 2018

CORRESPONDENCE

András Mester

Str. Gheorghe Marinescu nr. 38

540139 Tîrgu Mureş, Romania

Tel: +40 265 215 551

E-mail: andras.mester@yahoo.com

INTRODUCTION

The increasing prevalence of patients with overlapped cardiovascular and digestive symptoms has become a challenging problem in the daily practice.^{1,2} Cardiovascular and digestive diseases frequently share the same risk factors such as obesity, unhealthy diet, or several social behaviors. Furthermore, antithrombotic therapies used

for preventive or curative purposes in patients with cardiovascular diseases are frequently associated with gastrointestinal side effects including bleeding.³ Patients with gastro-esophageal reflux disease (GERD) can also exhibit various forms of chest pain that can be very similar to angina.⁴ Therefore, the complex relationship between gastrointestinal diseases and acute chest pain has been

extensively studied in order to reduce the mortality risk associated to chest pain with unknown etiology.⁵⁻⁷

In patients with acute chest pain, initiation of an adequate diagnostic strategy is essential for elucidating the etiology of chest pain. Due to the devastating consequences of misdiagnosing an acute coronary syndrome (ACS), the first diagnostic approach should be oriented towards the confirmation or exclusion of a significant coronary artery disease (CAD) as the source of chest pain. In the eventuality that CAD has been ruled out, the next step of evaluation is frequently represented by upper digestive endoscopy for diagnosing a possible gastrointestinal disease as the source of the chest pain. Such gastrointestinal etiology of angina-like symptoms could be represented by GERD, gastritis, or gastro-duodenal ulcer.⁵ However, due to the low prevalence of mucosal findings in patients with GERD, endoscopy is nowadays considered of limited value in patients with non-cardiac chest pain.^{6,7} In many cases with endoscopy-negative non-cardiac chest pain, the etiology of the angina-like symptoms can be functional or psychiatric.³

It has also been shown that patients with severe GERD-related symptoms had an increased risk of developing atrial fibrillation (AF), and treatment with proton pump inhibitors may facilitate conversion to sinus rhythm. However, the current studies did not succeed to demonstrate the casual relationship between GERD and AF.⁸

The use of dual antiplatelet therapy (DAPT), consisting in clopidogrel plus low-dose aspirin, significantly reduced cardiovascular mortality in patients suffering an acute myocardial infarction (AMI) and in those undergoing a percutaneous coronary intervention (PCI), however with the cost of increasing the rate of gastrointestinal (GI) events, including bleeding.^{3,9,10} Therefore, the management of patients with cardiovascular diseases who are on DAPT and present recurrent chest pain mimicking angina can be challenging in many clinical settings.¹¹

The aim of this review was to present the complex inter-relation between gastroesophageal diseases and chest pain in patients on dual antiplatelet therapy following an acute coronary syndrome, with a particular emphasis on the role of anemia resulting from occult or manifest gastrointestinal bleeding, as a precipitating factor for triggering or aggravating angina.

DUAL ANTIPLATELET THERAPY IN ACUTE CARDIAC CARE

Selection of the most appropriate antiplatelet therapy in acute cardiac care depends largely on the clinical set-

ting. Platelet inhibition is one of the main pharmacologic treatment goals in patients presenting with ACS. This is realized through inhibition of both the thromboxane A₂-dependent route (by administration of aspirin) and adenosine diphosphate P₂Y₁₂ receptor inhibition (by administration of ticagrelor, clopidogrel, or prasugrel).¹² According to current guidelines and recommendations of the European Society of Cardiology (ESC), patients undergoing PCI for an ACS should be initiated with DAPT as soon as the diagnosis is established, if no contraindications are present.¹³

The optimal dosage of aspirin therapy to maximize the platelet inhibition with minimized bleeding risk is not well established so far. Currently, a loading dose of 150–300 mg oral aspirin is recommended in post-PCI patients; however, recent trials evidenced that single intravenous administration of 250 or 500 mg of aspirin is superior in terms of thromboxane inhibition, with no increased bleeding risk compared to the administration of 300 mg of oral aspirin.¹⁴ Administration of 180 mg loading dose ticagrelor along with aspirin, continued with 90 mg twice daily is recommended irrespective of the previous antiplatelet therapy. In a large clinical trial which included 18,624 patients with ACS, ticagrelor was associated with significantly lower rates of major adverse cardiovascular events (such as cardiovascular death rates, myocardial infarction, and stroke), without a significant increase in major bleedings (11.6% vs. 11.2%, $p = 0.43$) compared to clopidogrel in a loading dose of 300 to 600 mg continued with 75 mg daily.¹⁵

The only P₂Y₁₂ inhibitor investigated in large clinical trials in patients who received thrombolytic therapy for an ST-elevation myocardial infarction (STEMI) was clopidogrel. Administration on top of aspirin in this patient category was associated with lower adverse ischemic event rates, with no significant increase in major bleedings, thus a 300 mg loading dose, continued with 75 mg daily is recommended in patients younger than 75 years.^{16,17} For those older than 75 years, there is no sufficient data about the safety and benefits of clopidogrel, thus the decision of a loading dose and further administration should be made individually, assessing the bleeding risk.¹³

In patients who present indication for oral anticoagulation (OAC), adding DAPT to OAC significantly increased bleeding events, hence an additional bleeding risk assessment (using HAS-BLED or ABC scores) is essential for establishing the duration of triple therapy.¹⁸ Administration of 600 mg clopidogrel loading dose, continued with 75 mg daily is currently recommended in the setting of an ACS.¹³

INTERACTION BETWEEN PROTON PUMP INHIBITORS AND ANTIPLATELETS IN THE CURRENT ERA – MYTH OR REALITY?

A large number of clinical trials investigated the lowest efficient dose for platelet inhibition to minimize the rate of hemorrhagic complications, as gastrointestinal bleedings are one of the most frequently reported adverse events in patients taking DAPT, and multiple sub-studies of these trials demonstrated the efficiency of proton pump inhibitors (PPI) in reduction of gastrointestinal bleeding risk for patients under antiplatelet therapy.²⁰ Thus, current ESC Guidelines recommend the administration of PPIs in combination with DAPT.^{13,22,23}

The question of pharmacological interaction between antiplatelet drugs and PPIs arose from the fact that both clopidogrel and PPIs are metabolized by the liver through cytochrome P450 or CYP enzymes. Pharmacologic studies suggested that omeprazole and esomeprazole inhibit isoenzyme CYP2C19 (which is used for the metabolic activation of clopidogrel), leading to decreased antiplatelet activity of clopidogrel in concomitant administration. This inhibition may be even augmented in some genetic variations of the CYP2C19 isoenzyme.^{24–26}

In a randomized double-blind study, Furtado *et al.* evidenced a significant decrease in inhibition of platelet activity ($26.3 \pm 32.9\%$ to $17.4 \pm 33.1\%$, $p = 0.025$) at one week follow-up when 20 mg omeprazole twice daily was added to 75 mg clopidogrel therapy in patients with stable coronary artery disease.²⁸ In an observational study on a general population of 2.9 million subjects, a 1.16-fold increase (95% CI: 1.09–1.24) of myocardial infarction was observed in patients with PPI therapy regardless of clopidogrel use.²⁹ A systematic review carried out by Sherwood *et al.*, which analyzed 6 observational studies, concluded that the concomitant use of clopidogrel and pantoprazole (HR: 1.38, 95% CI: 1.12–1.70), lansoprazole (HR: 1.29, 95% CI: 1.09–1.52), or esomeprazole (HR: 1.27, 95% CI: 1.02–1.58) is associated with higher risk of cardiovascular events.³⁰

The COGENT study, a randomized double blind, placebo-controlled trial, which included 3,761 patients undergoing stent implantation for ACS or stable coronary artery disease, analyzed and compared the safety and efficacy of 75 mg clopidogrel administration versus concomitant administration of clopidogrel and 20 mg omeprazole. A significant reduction in the rate of gastrointestinal clinical events was observed at the 180-day follow-up in patients in whom omeprazole was added, compared to the placebo group (1.1% vs. 2.9%, $p < 0.001$). Adversely, no significant increase was recorded in terms of adverse cardiovascular

events in the group of patients that received omeprazole versus the placebo group (4.9%, 95% CI: 3.4–6.4% vs. 5.7%, 95% CI 4–7.3%, $p = 0.98$).²² However DAPT with ticagrelor or prasugrel is associated with higher bleeding risk compared to clopidogrel, and there are no randomized studies so far to investigate the risks and benefits of the concomitant use of these antiplatelet agents with PPIs.

Currently, the data obtained from randomized controlled trials is lacking convincing clinical evidence that supports the negative effect of PPIs in patients with indication for DAPT.

GASTROINTESTINAL SIDE EFFECTS OF DUAL ANTIPLATELET THERAPY

Two major gastrointestinal side effects have been described in relation to antithrombotic therapy: angina-like symptoms caused by mucosal damage, which is more frequent in the upper digestive tract, and bleeding, which can occur from the upper or lower digestive tract. The mechanisms of gastric mucosal damage caused by aspirin involve the systemic inhibition of cyclooxygenase (COX-1 and COX-2) and consequently gastric prostaglandin synthesis, as well as local inflammatory reaction mediated by cytokines.³¹ Additionally, clopidogrel delays the healing of the gastric mucosa via impairment of angiogenesis, leading to an increased risk of a gastrointestinal bleeding episode in comparison with aspirin alone.^{32–34}

The effect of DAPT, or generally antithrombotic drugs, on the lower digestive tract is not very well known. Unlike the upper digestive tract, where endoscopic lesions are easily detected using endoscopy, and the effectiveness of preventive strategies such as proton pump inhibitors use or *Helicobacter pylori* eradication has been well demonstrated, the effects of DAPT on the lower digestive tract are less well known. The most important and largest study investigating the bleeding risk of DAPT (CHARISMA) did not offer data regarding the site of bleeding.³² Recent data suggest that bleeding from the small and large intestine associated with antithrombotic drugs plays a significant role in hospital readmission rate or increased mortality.^{35,36}

In a retrospective Chinese study investigating the etiology of gastrointestinal bleeding in 114 patients with a first episode of bleeding while on DAPT, the incidence of upper (53.5% vs. 51.3%) and lower (46.5% vs. 48.7%) gastrointestinal bleeding was similar irrespective of DAPT use, but a much higher proportion of the DAPT group had no source of bleeding identified even after an extensive workup, underling that patients are more prone to bleed from an occult lesion.³⁷

A prospective Japanese study based on endoscopy (colonoscopy, $n = 319$) proved that the association of low-dose aspirin with thienopyridines was associated with a significantly lower risk of digestive bleeding (OR: 2.2, 95% CI: 1.1–4.5).³⁸ Nevertheless, there are data sustaining that bleeding risk associated to gastrointestinal endoscopic procedures in patients under DAPT are scarce and poor-quality and do not sustain the cessation of clopidogrel for endoscopic procedures.^{39,40} On the other hand, in patients with lower gastrointestinal bleeding, antiplatelet drugs are more prone to be related to recurrent bleeding in comparison with patients on warfarin or OACs.⁴¹

STENT THROMBOSIS AND ANTIPLATELET THERAPY

Patients having implanted coronary stents represent a distinct population with specific risks. For instance, patients with history of stent thrombosis are at high risk for recurrent thrombotic events. It has been demonstrated that clopidogrel is associated with significantly higher recurrent stent thrombosis rates compared to ticagrelor or prasugrel. Therefore, the administration of ticagrelor or prasugrel is recommended over clopidogrel in patients presenting with an ACS in the context of a stent thrombosis, and this therapy should be maintained for the long term.^{15,42} The optimal duration of DAPT should be assessed based on validated risk scores such as the PRECISE-DAPT (at the moment of stent implantation) or DAPT score (after one year of uneventful DAPT), which evaluate the ischemic and bleeding risk of patients with stent implantation and offer guidance for DAPT duration.^{43,44}

ETIOLOGY OF ACUTE CHEST PAIN IN PATIENTS WITH CORONARY STENTS

Acute chest pain is one of the most frequent complain of patients presenting at the emergency department, and approximately 20–25% of these patients are diagnosed with an ACS.⁴⁵

In patients with coronary stents presenting to the emergency department with chest pain, angina triggered by stent thrombosis or restenosis should be differentiated from angina-like symptoms caused by a gastrointestinal disease.

Other frequent etiologies of chest pain include musculoskeletal, pulmonary, gastrointestinal, and psychiatric diseases.⁴⁶ In emergency settings, it is paramount to rule out the major life-threatening conditions that may serve as an underlying cause for acute chest pain. These

pathologies include acute myocardial infarction, aortic dissection, pulmonary artery embolism, tension pneumothorax, and Boerhaave syndrome.⁴⁷ Physical examination, recording of a 12-lead electrocardiogram (ECG), clinical chemistry (hemoglobin, white blood cell count, troponin, myoglobin, creatine-kinase levels), and imaging studies such as echocardiography, chest X-ray, or computed tomography angiography are essential for a quick, proper diagnosis.⁴⁶

Patients who underwent PCI with coronary stent implantation are still at risk of developing recurrent ischemic events, and approximately 30–35% of these patients return complaining about chest pain. The underlying cause of acute chest pain is mostly represented by acute stent thrombosis, incomplete revascularization, in-stent restenosis (ISR), or the progression of non-culprit atheromatous lesions.^{48,49} Despite the fact that the rate of ISR has been significantly reduced in the drug-eluting stent (DES) era, it still represents a major issue for the health-care system.⁵⁰ A large number of these patients present an ACS with subsequent ECG and laboratory changes. In a clinical trial which analyzed 110 patients with clinically manifested ISR at a follow-up of minimum one year, Marino *et al.* stated that 62.7% of the patients presented with an ACS.⁵¹ ACS as clinical presentation remains unchanged irrespective of stent type, as Magalhaes *et al.*, in a study on 909 subjects, reported similar rates in patients with implanted bare metal stent (BMS) and first- and second-generation DES (67.8% vs. 71% vs. 66.7%, respectively, $p = 0.47$).⁵² A high rate of post-PCI chest pain is also recorded in patients with stable CAD. In a study which included 167 patients who underwent elective PCI for stable CAD, Chang *et al.* reported an incidence of 41.9% of post-PCI chest pain.⁵³

ANEMIA FOLLOWING GASTROINTESTINAL BLEEDING – A PRECIPITATING FACTOR FOR POST-STENTING ANGINA

In patients with implanted stents, a significant precipitating factor for developing recurrent ischemic events is represented by anemia that can result from occult or manifest gastrointestinal bleeding. Figure 1 summarizes the approach of patients with implanted coronary stents presenting with chest pain and the role of anemia as precipitating factor for developing angina.

A recent study conducted by Giustino *et al.* in patients on DAPT for an implanted DES revealed that compared to patients with normal hemoglobin levels, those with anemia presented significantly higher rates of major adverse

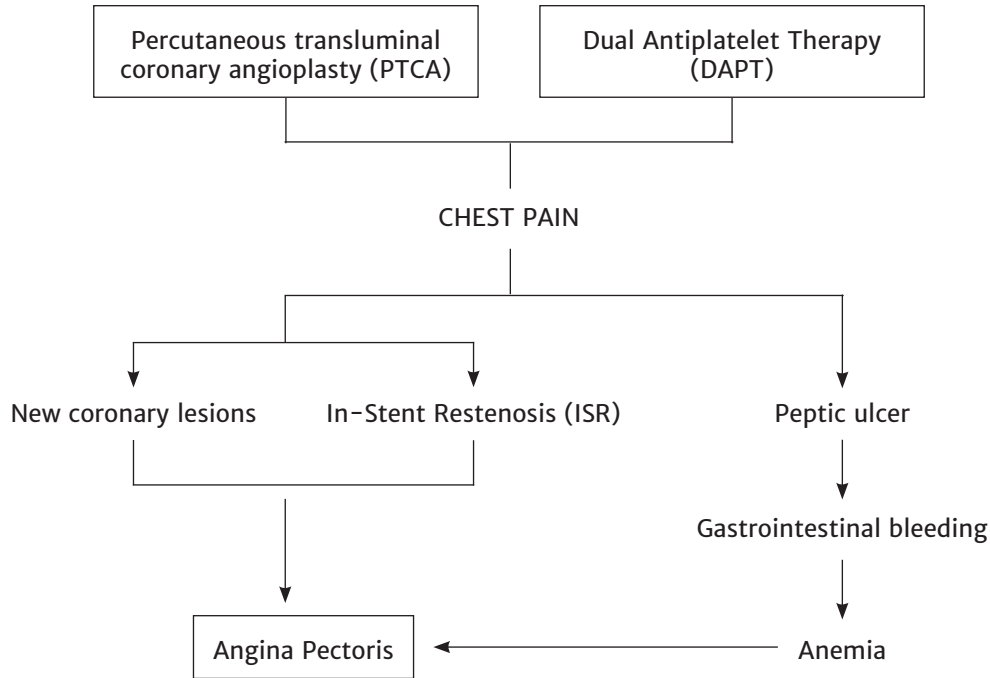


FIGURE 1. The approach of patients with implanted coronary stents presenting with chest pain and the role of anemia as precipitating factor for developing angina

cardiovascular events (9.5% vs. 5.6%, $p < 0.0001$), all-cause mortality (4.0% vs. 1.4%, $p < 0.0001$), as well as major bleeding events (11.8% vs. 7.7%, $p < 0.0001$).⁵⁴ Patients on DAPT are at an increased risk of developing both upper and lower gastrointestinal bleeding events, which can subsequently lead to serious anemia in this fragile population.^{55,56} In a recent large cohort study which included 27,707 patients, Gonzalez-Perez *et al.* concluded that 73% of patients with upper gastrointestinal bleeding and 23% of those with lower gastrointestinal bleeding, being on antiplatelet therapy for a serious coronary event, needed hospitalization.⁵⁷ In an observational study which included 122 patients, DAPT was associated with a significant decrease of hemoglobin levels (1.6, 95% CI: 1.2–1.8, $p < 0.001$) and an increased prevalence of anemia after DAPT (9.1% vs. 45.9%).

MANAGEMENT OF GASTROINTESTINAL BLEEDING IN PATIENTS WITH CORONARY STENTS

In case of hemorrhage in a patient on DAPT, with a recently implanted coronary stent, a life-threatening complication could occur if the therapy is interrupted. The standard attitude, after adequate resuscitation, is prompt endoscopic hemostasis within the gastrointestinal tract, and good facilities and specialists should be available to provide this.⁵⁸

In case of patients with coronary stents, whenever it is deemed necessary to temporarily discontinue antiplatelet therapy, this should be limited to the P2Y12 inhibitor, but aspirin should be continued.

Even if there is no good-quality prospective study to evaluate the optimal time for cessation of therapy, the P2Y12 inhibitor should be restarted within a maximum of 5 days due to the high risk of stent thrombosis after this time, and to obtain the most suitable balance between hemorrhage and thrombosis risk.⁵⁹ A retrospective study in elective or acute settings of PCI sustained a frequency of 10.2% of bleeding complication within 1 year after the procedure, with no increase in mortality risk.⁶⁰ Dual anti-thrombotic therapy had a higher risk than single therapy for rebleeding in the lower digestive tract in a retrospective study (adjusted HR 1.8, $p < 0.05$), 46% of all patients had rebleeding, and the overall mortality rate was 13% within 5 years after hospitalization.³⁶

There are published data indicating no significant differences in the cardiovascular outcomes and safety between post-PCI patients on DAPT continuing antiplatelet monotherapy with aspirin and experiencing a gastrointestinal hemorrhage, even if, in terms of recurrent bleeding, antiplatelet monotherapy remains beneficial.⁶¹ One of the most important known risk factors for gastrointestinal bleeding in the upper digestive tract in patients on aspirin

therapy is a history of complicated or uncomplicated ulcer, that increases the risk two or three times.^{3,21} Patients who need continuous combined antithrombotics present two concomitant important risk factors, while standard preventive therapy with PPI does not influence the risk of lower endoscopic bleeding sources. Despite guideline recommendations for gastroprotective therapy in patients with dual antiplatelet therapy, only 60% of patients who required protective therapy were on PPIs in studies involving a Romanian population.^{3,19} The results are very similar with studies published elsewhere, sustaining the relatively low adherence to protective therapy in patients with bleeding risk.⁶² Nonetheless, a recent meta-analysis sustains that all gastroprotective therapies reduced further bleeding (OR: 0.68, $p < 0.0001$), blood transfusion (OR: 0.75, $p = 0.0003$), further endoscopic intervention (OR: 0.56, $p < 0.0001$), or surgery (OR: 0.72, $p < 0.0001$), but did not significantly reduce mortality (OR: 0.90, $p = 0.31$), supporting the importance of careful assessment of good balance between ischemic and bleeding risk in cardiac patients.⁶³

HELICOBACTER PYLORI – A SILENT ENEMY IN PATIENTS WITH CORONARY STENTS

The interaction between aspirin and *H. pylori* infection in the upper digestive tract is not fully understood, some studies sustaining an increased risk for bleeding in infected patients on treatment with aspirin, while others do not support this association.^{64,65} The possible causes of discordant results could be the inhomogeneous nature of these studies, being conducted in populations with various genetic backgrounds or different characteristics of the *H. pylori* infection. Apart from decreased prostaglandin synthesis influencing the local protective mechanisms of the gastric mucosa, the damaging mechanism initiated by aspirin involves the role of inflammatory cytokines.⁶⁶ This mechanism acts synergistically with the *H. pylori* infection, leading to the accumulation of inflammatory infiltrate in the gastric mucosa and increased acid secretion, at least in the first stages of infection.⁶⁷ Adding P2Y12 inhibitors to aspirin can favor the lesion of the gastric mucosa and promotes bleeding from any other type of mucosal lesions in patients after PCI, further increasing the risk of bleeding.⁶⁸

On the other hand, *H. pylori* has been suggested to be a possible contributor to CAD progression, both via inducing a systemic inflammation or via direct aggression on the vessel wall, with a possible role even in ACSs.^{69–71} Despite the controversial results of different studies taking into account the complex gastric and extragastric effects of *H. pylori* infection in the human body, the infection should be care-

fully assessed in cardiac patients with coronary stents on DAPT.^{72,73} The possible preventive role of *H. pylori* infection assessment in a cardiac population which required combined antithrombotic therapy has not been clarified so far, due to differences in infection prevalence worldwide, as well as to differences in population characteristics in terms of genetic background or specific environmental factors.^{27,28,67} The majority of published work supports the beneficial effect of adding PPI to a combined antiplatelet therapy for gastro-duodenal lesions, with a more important effect in the population characterized by a high frequency of *H. pylori* infection.⁷⁴ At the same time, the childhood acquisition of *H. pylori* infection increases the burden of ulcer history, which further increases the risk of bleeding complications at adult age in patients with CAD who require DAPT. This interrelation seems to be related to mucosal scar vulnerability and, probably, to the lack of any effective therapy for *H. pylori* eradication in patients with previous ulcers.^{3,21}

CONCLUSIONS

In conclusion, DAPT significantly reduced cardiovascular mortality in patients undergoing percutaneous coronary revascularization and stenting, however, with the cost of increasing the risk of bleeding. The management of patients with prior coronary stenting who are on DAPT and present recurrent chest pain mimicking angina can be challenging in many clinical settings. In these cases, angina triggered by stent thrombosis or restenosis should be differentiated from angina-like symptoms caused by a gastrointestinal disease, and anemia resulting from occult or manifest gastrointestinal bleeding should be promptly diagnosed as it can represent the precipitating factor for triggering or aggravating angina.

CONFLICT OF INTEREST

Nothing to declare.

ACKNOWLEDGEMENT

This research was supported by an intern research grant of the University of Medicine and Pharmacy of Tîrgu Mureş, Romania, contract number 11/23.12.2014.

REFERENCES

1. Bhuiya FA, Pitts SR, McCaig LF. Emergency department visits for chest pain and abdominal pain: United States, 1999–2008. NCHS Data Brief. 2010;43:1–8.

2. Fass R, Achem SR. Noncardiac chest pain: epidemiology, natural course and pathogenesis. *J Neurogastroenterol Motil.* 2011;17:110-123. doi: 10.5056/jnm.2011.17.2.110.
3. Bhatt DL, Scheiman J, Abraham NS, et al. American College of Cardiology Foundation Task Force on Clinical Expert Consensus Documents. ACCF/ACG/AHA 2008 expert consensus document on reducing the gastrointestinal risks of antiplatelet therapy and NSAID use: a report of the American College of Cardiology Foundation Task Force on Clinical Expert Consensus Documents. *Circulation.* 2008;118:1894-1909. doi: 10.1161/CIRCULATIONAHA.108.191087.
4. Richter JE. Chest pain and gastroesophageal reflux disease. *J Clin Gastroenterol.* 2000;30:S39-S41.
5. Aziz Q, Fass R, Gyawali CP, Miwa H, Pandolfino JE, Zerbib F. Functional esophageal disorders. *Gastroenterology.* 2016;150:1368-1379. doi: 10.1053/j.gastro.2016.02.012.
6. Herregods TVK, Bredenoord AJ, Oors JM, Bogte A, Smout AJPM. Determinants of the Association between Non-Cardiac Chest Pain and Reflux. *Am J Gastroenterol.* 2017;112:1671-1677. doi: 10.1038/ajg.2017.288.
7. Faybush EM, Fass R. Gastroesophageal reflux disease in noncardiac chest pain. *Gastroenterol Clin North Am.* 2004;33:41-54.
8. Roman C, Bruley des Varannes S, Muresan L, Picos A, Dumitrascu DL. Atrial fibrillation in patients with gastrointestinal reflux disease: a comprehensive review. *World J Gastroenterol.* 2014; 20:9592-9599. doi: 10.3748/wjg.v20.i28.9592.
9. Anderson JL, Adams CD, Antman EM, et al. American Heart Association Task Force on Practice Guidelines; American College of Emergency Physicians; Society for Cardiovascular Angiography and Interventions; Society of Thoracic Surgeons; American Association of Cardiovascular and Pulmonary Rehabilitation; Society for Academic Emergency Medicine: ACC/AHA 2007 guidelines for the management of patients with unstable angina/non ST-elevation myocardial infarction: a report of the American College of Cardiology/American Heart Association Task Force on Practice Guidelines. *Circulation.* 2007;116:e148e304. doi: 10.1016/j.jacc.2007.02.013
10. Kushner FG, Hand M, Smith Jr SC, et al. 2009 focused updates: ACC/AHA guidelines for the management of patients with ST-elevation myocardial infarction (updating the 2004 guideline and 2007 focused update) and ACC/AHA/SCAI guidelines on percutaneous coronary intervention (updating the 2005 guideline and 2007 focused update) a report of the American College of Cardiology Foundation/American Heart Association Task Force on Practice Guidelines. *J Am Coll Cardiol.* 2009;54:2205e41. doi: 10.1016/j.jacc.2009.10.015.
11. Egholm G, Thim T, Madsen M, et al. Gastroscopy-related adverse cardiac events and bleeding complications among patients treated with coronary stents and dual antiplatelet therapy. *Endosc Int Open.* 2016;4:E527-E533. doi: 10.1055/s-0042-102649.
12. Patrono C, Andreotti F, Arnesen H, et al. Antiplatelet agents for the treatment and prevention of atherothrombosis. *Eur Heart J.* 2011;32:2922-2932. doi: 10.1093/eurheartj/ehr373.
13. Valgimigli M, Bueno H, Byrne RA, et al. 2017 ESC focused update on dual antiplatelet therapy in coronary artery disease developed in collaboration with EACTS. *Eur J Cardiothorac Surg.* 2018;53:34-78. doi: 10.1093/ejcts/ezx334.
14. Zeymer U, Hohlfeld T, Vom Dahl J, et al. Prospective, randomised trial of the time dependent antiplatelet effects of 500 mg and 250 mg acetylsalicylic acid i. v. and 300 mg p. o. in ACS (ACUTE). *Thromb Haemost.* 2017;117:625-635. doi: 10.1160/TH16-08-0650.
15. Wallentin L, Becker RC, Budaj A, et al. Ticagrelor versus clopidogrel in patients with acute coronary syndromes. *N Engl J Med.* 2009;361:1045-1057. doi: 10.1056/NEJMoa0904327.
16. Sabatine MS, Cannon CP, Gibson CM, et al. Addition of clopidogrel to aspirin and fibrinolytic therapy for myocardial infarction with ST-segment elevation. *N Engl J Med.* 2005;352:1179-1189. doi: 10.1056/NEJMoa050522.
17. Chen ZM, Jiang LX, Chen YP, et al. Addition of clopidogrel to aspirin in 45,852 patients with acute myocardial infarction: randomised placebo-controlled trial. *Lancet.* 2005;366:1607-1621. doi: 10.1016/S0140-6736(05)67660-X.
18. Sorensen R, Hansen ML, Abildstrom SZ, et al. Risk of bleeding in patients with acute myocardial infarction treated with different combinations of aspirin, clopidogrel, and vitamin K antagonists in Denmark: a retrospective analysis of nationwide registry data. *Lancet.* 2009;374:1967-1974. doi: 10.1016/S0140-6736(09)61751-7.
19. Negovan A, Iancu M, Moldovan V, et al. The contribution of clinical and pathological predisposing factors to severe gastro-duodenal lesions in patients with long-term low-dose aspirin and proton pump inhibitor therapy. *Eur J Intern Med.* 2017;44:62-66. doi: 10.1016/j.ejim.2017.05.017.
20. Agewall S, Cattaneo M, Collet JP, et al. Expert position paper on the use of proton pump inhibitors in patients with cardiovascular disease and antithrombotic therapy. *Eur Heart J.* 2013;34:1708-1713, 1713a-1713b. doi: 10.1093/eurheartj/eh042.
21. Negovan A, Iancu M, Moldovan V, et al. Clinical Risk Factors for Gastroduodenal Ulcer in Romanian Low-Dose Aspirin Consumers. *Gastroenterol Res Pract.* 2016;2016:7230626. doi: 10.1155/2016/7230626.
22. Bhatt DL, Cryer BL, Contant CF, et al. Clopidogrel with or without omeprazole in coronary artery disease. *N Engl J Med.* 2010;363:1909-1917. doi: 10.1056/NEJMoa1007964.
23. Gargiulo G, Costa F, Ariotti S, et al. Impact of proton pump inhibitors on clinical outcomes in patients treated with a 6- or 24-month dual-antiplatelet therapy duration: Insights from the PROlonging Dual-antiplatelet treatment after Grading stent-induced Intimal hyperplasia study trial. *Am Heart J.* 2016;174:95-102. doi: 10.1016/j.ahj.2016.01.015.
24. Sibbing D, Morath T, Stegherr J, et al. Impact of proton pump inhibitors on the antiplatelet effects of clopidogrel. *Thromb Haemost.* 2009;101:714-719.
25. Gilard M, Arnaud B, Cornily JC, et al. Influence of omeprazole on the antiplatelet action of clopidogrel associated with aspirin: the randomized, double-blind OCLA (Omeprazole CLopidogrel Aspirin) study. *J Am Coll Cardiol.* 2008;51:256-260. doi: 10.1016/j.jacc.2007.06.064.
26. Simon N, Finzi J, Cayla G, et al. Omeprazole, pantoprazole, and CYP2C19 effects on clopidogrel pharmacokinetic-pharmacodynamic relationships in stable coronary artery disease patients. *Eur J Clin Pharmacol.* 2015;71:1059-1066. doi: 10.1007/s00228-015-1882-3.
27. Negovan A, Voidăzan S, Pantea M, et al. The AGT A-20 C gene polymorphism is associated with ulcer in Romanian patients treated with low-dose aspirin. *Rev Romana Med Lab.* 2015;23:179-187. doi: <https://doi.org/10.1515/rmlm-2015-0017>.

28. Furtado RH, Giugliano RP, Strunz CM, et al. Drug Interaction Between Clopidogrel and Ranitidine or Omeprazole in Stable Coronary Artery Disease: A Double-Blind, Double Dummy, Randomized Study. *Am J Cardiovasc Drugs*. 2016;16:275-284. doi: 10.1007/s40256-016-0172-5.
29. Shah NH, LePendou P, Bauer-Mehren A, et al. Proton pump inhibitor usage and the risk of myocardial infarction in the general population. *PLoS One* 2015;10:e0124653. doi: 10.1371/journal.pone.0124653.
30. Sherwood MW, Melloni C, Jones WS, et al. Individual Proton Pump Inhibitors and Outcomes in Patients With Coronary Artery Disease on Dual Antiplatelet Therapy: A Systematic Review. *J Am Heart Assoc*. 2015;4: e002245. doi: 10.1161/JAHA.115.002245.
31. Ng SC, Chan FK. NSAID-induced gastrointestinal and cardiovascular injury. *Curr Opin Gastroenterol*. 2010;26:611-617. doi: 10.1097/MOG.0b013e32833e91eb.
32. Berger PB, Bhatt DL, Fuster V, et al. CHARISMA Investigators. Bleeding complications with dual antiplatelet therapy among patients with stable vascular disease or risk factors for vascular disease: results from the Clopidogrel for High Atherothrombotic Risk and Ischemic Stabilization, Management, and Avoidance (CHARISMA) trial. *Circulation*. 2010;121:2575-2583. doi: 10.1161/CIRCULATIONAHA.109.895342.
33. Valkhoff VE, Sturkenboom MC, Kuipers EJ. Risk factors for gastrointestinal bleeding associated with low-dose aspirin. *Best Pract Res Clin Gastroenterol*. 2012;26:125-140. doi: 10.1016/j.bpg.2012.01.011.
34. Tsai TJ, Lai KH, Hsu PI, et al. Upper gastrointestinal lesions in patients receiving clopidogrel anti-platelet therapy. *J Formos Med Assoc*. 2012;111:705-710. doi: 10.1016/j.jfma.2011.11.028.
35. Sengupta N, Tapper EB, Patwardhan VR, et al. Risk Factors for Adverse Outcomes in Patients Hospitalized With Lower Gastrointestinal Bleeding. *Mayo Clin Proc*. 2015;90:1021-1029. doi: 10.1016/j.mayocp.2015.04.024.
36. Aoki T, Nagata N, Niikura R, et al. Recurrence and mortality among patients hospitalized for acute lower gastrointestinal bleeding. *Clin Gastroenterol Hepatol*. 2015;13:488-494. doi: 10.1016/j.cgh.2014.06.023.
37. Shaukat A, Waheed S, Alexander E, et al. Etiology of gastrointestinal bleeding in patients on dual antiplatelet therapy. *J Dig Dis*. 2018;19:66-73. doi: 10.1111/1751-2980.12575.
38. Nagata N, Niikura R, Aoki T, et al. Lower GI bleeding risk of nonsteroidal anti-inflammatory drugs and antiplatelet drug use alone and the effect of combined therapy. *Gastrointest Endosc*. 2014;80:1124-1131. doi: 10.1016/j.gie.2014.06.039.
39. Abdel Samie A, Theilmann L. Endoscopic procedures in patients under clopidogrel/dual antiplatelet therapy: to do or not to do? *J Gastrointest Liver Dis*. 2013;22:33-36.
40. Carlin N, Asslo F, Sison R, Shaaban H, Baddoura W, Manji F, Depasquale J. Dual Antiplatelet Therapy and the Severity Risk of Lower Intestinal Bleeding. *J Emerg Trauma Shock*. 2017;10:98-102. doi: 10.4103/JETS.JETS_110_15.
41. Oakland K, Desborough MJ, Murphy MF, Schachter M, Jairath V. Re-bleeding and Mortality After Lower Gastrointestinal Bleeding in Patients Taking Anti-platelets or Anti-coagulants. *Clin Gastroenterol Hepatol*. 2017;pii:S1542-3565(17)31528-8. doi: 10.1016/j.cgh.2017.12.032.
42. Wiviott SD, Braunwald E, McCabe CH, et al. Prasugrel versus clopidogrel in patients with acute coronary syndromes. *N Engl J Med*. 2007;357:2001-2015. doi: 10.1056/NEJMoa0706482.
43. Yeh RW, Secemsky EA, Kereiakes DJ, et al. Development and validation of a prediction rule for benefit and harm of dual antiplatelet therapy beyond 1 year after percutaneous coronary intervention. *JAMA*. 2016;315:1735-1749. doi: 10.1001/jama.2016.3775.
44. Costa F, van Klaveren D, James S, et al. Derivation and validation of the predicting bleeding complications in patients undergoing stent implantation and subsequent dual antiplatelet therapy (PRECISE-DAPT) score: a pooled analysis of individual-patient datasets from clinical trials. *Lancet*. 2017;389:1025-1034. doi: 10.1016/S0140-6736(17)30397-5.
45. Christ M, Popp S, Pohlmann H, et al. Implementation of high sensitivity cardiac troponin T measurement in the emergency department. *Am J Med*. 2010;123:1134-1142. doi: 10.1016/j.amjmed.2010.07.015.
46. Erhardt L, Herlitz J, Bossaert L, et al. Task force on the management of chest pain. *Eur Heart J*. 2002;23:1153-1176.
47. Bruno RR, Donner-Banzhoff N, Söllner W, et al. The Interdisciplinary Management of Acute Chest Pain. *Dtsch Arztebl Int*. 2015;112:768-779; quiz 780. doi: 10.3238/arztebl.2015.0768.
48. Schüepf M, Ullmer E, Weinbacher M, et al. Chest pain early after percutaneous coronary intervention: incidence and relation to ECG changes, cardiac enzymes and follow-up events. *J Invasive Cardiol*. 2001;13:211-216.
49. Kini AS, Lee P, Mitre CA, Duffy ME, Sharma SK. Postprocedure chest pain after coronary stenting: implications on clinical restenosis. *J Am Coll Cardiol*. 2003;41:33-38.
50. Dangas GD, Claessen BE, Caixeta A, Sanidas EA, Mintz GS, Mehran R. In-stent restenosis in the drug-eluting stent era. *J Am Coll Cardiol*. 2010;56:1897-907. doi: 10.1016/j.jacc.2010.07.028.
51. Marino BC, Nascimento GA, Rabelo W, et al. Clinical Coronary In-Stent Restenosis Follow-Up after Treatment and Analyses of Clinical Outcomes. *Arq Bras Cardiol*. 2015;104:375-386. doi: 10.5935/abc.2014.0216.
52. Magalhaes MA, Minha S, Chen F, et al. Clinical presentation and outcomes of coronary in-stent restenosis across 3-stent generations. *Circ Cardiovasc Interv*. 2014;7:768-776. doi: 10.1161/CIRCINTERVENTIONS.114.001341.
53. Chang C, Chen Y, Ong E, et al. Chest pain after percutaneous coronary intervention in patients with stable angina. *Clin Interv Aging*. 2016;11:1123-1128. doi: 10.2147/CIA.S103605.
54. Giustino G, Kirtane AJ, Baber U, et al. Impact of Anemia on Platelet Reactivity and Ischemic and Bleeding Risk: From the Assessment of Dual Antiplatelet Therapy With Drug-Eluting Stents Study. *Am J Cardiol*. 2016;117:1877-1883. doi: 10.1016/j.amjcard.2016.03.034.
55. Casado Arroyo R, Polo-Tomas M, Roncales MP, et al. GI bleeding is more common than upper among patients on dual antiplatelet therapy: long-term follow-up of a cohort of patients commonly using PPI co-therapy. *Heart*. 2012;98:718-723. doi: 10.1136/heartjnl-2012-301632.
56. García Rodríguez LA, Lin KJ, Hernández-Díaz S, Johansson S. Risk of upper gastrointestinal bleeding with low-dose acetylsalicylic acid alone and in combination with clopidogrel and other medications. *Circulation*. 2011;123:1108-1115. doi: 10.1161/CIRCULATIONAHA.110.973008.
57. González-Pérez A, Sáez ME, Johansson S, Himmelmann A, García Rodríguez LA. Risk of bleeding after hospitalization for a serious coronary event: a retrospective cohort study

- with nested case-control analyses. *BMC Cardiovasc Disord.* 2016;16:164. doi: 10.1186/s12872-016-0348-6.
58. Veitch AM. Endoscopy in Patients on Antiplatelet Agents and Anticoagulants. *Curr Treat Options Gastroenterol.* 2017;15:256-267. doi: 10.1007/s11938-017-0137-z.
59. Eisenberg MJ, Richard PR, Libersan D, et al. Safety of short-term discontinuation of antiplatelet therapy in patients with drug-eluting stents. *Circulation.* 2009;119:1634-1642. doi: 10.1161/CIRCULATIONAHA.108.813667.
60. Sumayin Ngamdu K, El Mallah W, et al. One-Year Survival is Not Affected by Gastrointestinal Bleeding After Percutaneous Coronary Interventions. *Am J Med Sci.* 2017;353:381-386. doi: 10.1016/j.amjms.2017.01.017.
61. Guo Y, Wei J. Clinical outcomes of various continued antiplatelet therapies in patients who were administered DAPT following the implantation of drug-eluting stents and developed gastrointestinal hemorrhage. *Exp Ther Med.* 2016;12:1125-1129. doi: 10.3892/etm.2016.3378.
62. Jensen BES, Hansen JM, Larsen KS, et al. Randomized clinical trial: the impact of gastrointestinal risk factor screening and prophylactic proton pump inhibitor therapy in patients receiving dual antiplatelet therapy. *Eur J Gastroenterol Hepatol.* 2017;29:1118-1125. doi: 10.1097/MEG.0000000000000934.
63. Scally B, Emberson JR, Spata E, et al. Effects of gastroprotectant drugs for the prevention and treatment of peptic ulcer disease and its complications: a meta-analysis of randomised trials. *Lancet Gastroenterol Hepatol.* 2018;3:231-241. doi: 10.1016/S2468-1253(18)30037-2.
64. Lanás A, Bajador E, Serrano P, et al. Nitrovasodilators, low-dose aspirin, other nonsteroidal antiinflammatory drugs, and the risk of upper gastrointestinal bleeding. *N Engl J Med.* 2000;343:834-839. doi: 10.1056/NEJM200009213431202.
65. Fletcher EH, Johnston DE, Fisher CR, et al. Systematic review: *Helicobacter pylori* and the risk of upper gastrointestinal bleeding risk in patients taking aspirin. *Aliment Pharmacol Ther.* 2010;32:831-839. doi: 10.1111/j.1365-2036.2010.04415.x.
66. Sostres C, Gargallo CJ, Lanás A. Interaction between *Helicobacter pylori* infection, nonsteroidal anti-inflammatory drugs and/or low-dose aspirin use: old question new insights. *World J Gastroenterol.* 2014;20:9439-9450. doi: 10.1016/j.bpg.2012.01.006.
67. Leung Ki EL, Chan FK. Interaction of *Helicobacter pylori* infection and low-dose aspirin in the upper gastrointestinal tract: implications for clinical practice. *Best Pract Res Clin Gastroenterol.* 2012;26:163-172. doi: 10.3748/wjg.v20.i28.9439.
68. Tsai TJ, Lai KH, Hsu PI, et al. Upper gastrointestinal lesions in patients receiving clopidogrel anti-platelet therapy. *J Formos Med Assoc.* 2012;111:705-710. doi: 10.1016/j.jfma.2011.11.028.
69. Ayada K, Yokota K, Kobayashi K, Shoenfeld Y, Matsuura E, Oguma K. Chronic infections and atherosclerosis. *Ann N Y Acad Sci.* 2007;1108:594-602.
70. Tan HJ, Goh KL. Extragastric manifestations of *Helicobacter pylori* infection: facts or myth? A critical review. *J Dig Dis.* 2012;13:342-349. doi: 10.1111/j.1751-2980.2012.00599.x.
71. Liu J, Wang F, Shi S. *Helicobacter pylori* Infection Increase the Risk of Myocardial Infarction: A Meta-Analysis of 26 Studies Involving more than 20,000 Participants *Helicobacter.* 2015;20:176-183. doi: 10.1111/hel.12188.
72. Kanbay M, Gur G, Yucel M, Yilmaz U, Muderrisoglu H. *Helicobacter pylori* seroprevalence in patients with coronary artery disease. *Dig Dis Sci.* 2005;50:2071-2074. doi: 10.1007/s10620-005-3009-7.
73. Lee M, Baek H, Park JS, et al. Current *Helicobacter pylori* infection is significantly associated with subclinical coronary atherosclerosis in healthy subjects: A cross-sectional study. *PLoS One.* 2018;13:e0193646. doi: 10.1371/journal.pone.0193646.
74. Huang KW, Luo JC, Leu HB, et al. Risk factors for upper gastrointestinal bleeding in coronary artery disease patients receiving both aspirin and clopidogrel. *J Chin Med Assoc.* 2013;76:9-14.