

ORIGINAL RESEARCH

Diagnosis of the Aortic Coarctation in the Neonatal Period — a Critical Condition in the Emergency Room

Simina-Elena Rusu¹, Daniela Toma², Cristina Blesneac², Laura Matei², Claudiu Ghiragosian², Rodica Togănel²

¹County Emergency Clinical Hospital, Tîrgu Mureş, Romania

²Emergency Institute for Cardiovascular Diseases and Transplantation, Tîrgu Mureş, Romania

ABSTRACT

Background: Critical coarctation of the aorta is the most common congenital heart disease with ductal-dependent systemic circulation. In severe forms, this disease represents a critical condition, which can become life-threatening. The aim of this study was to evaluate the usefulness of different echocardiographic parameters in the prediction of aortic coarctation in newborns. **Material and method:** This is a retrospective study performed by reviewing echocardiographic images of both pre-term and full-term newborns presented with aortic coarctation to the emergency room of a clinic of pediatric cardiology. Based on echocardiographic measurements, both the common carotid artery-subclavian artery index (CSAi) and the aortic isthmus-descending aorta index (I/D) were calculated. **Results:** Fifty-two newborns presented in acute settings with aortic coarctation and were included in the study, divided into: subgroup 1 (n = 26) – ductal-dependent aortic coarctation; subgroup 2 (n = 2) – non-ductal-dependent aortic coarctation; and subgroup 3 (n = 24) – unconfirmed aortic coarctation. ROC analysis identified a cutoff value of 1.37 for the CSAi index and a cutoff value of 0.46 for the I/D index as being associated with the highest predictive power for the diagnosis of aortic coarctation. **Conclusions:** The CSAi and I/D indices are simple and accessible echocardiographic parameters that can provide supplemental information for the pediatric cardiologist in acute cases of newborns with suspicion of aortic coarctation. These new indices can contribute to the decision-making process in case of pre-term and full-term newborns with suspicion of coarctation of the aorta, independent of the presence of persistent ductus arteriosus.

Keywords: neonatal aortic coarctation, echocardiographic indexes, patent ductus arteriosus

ARTICLE HISTORY

Received: August 15, 2017

Accepted: September 13, 2017

CORRESPONDENCE

Cristina Blesneac

Str. Gheoghe Marinescu nr. 50
540136 Tîrgu Mureş, Romania
Tel: +40 744 794 663

E-mail: cristinablesneac@yahoo.com

INTRODUCTION

Aortic coarctation is a disease represented by a congenital narrowing of the aortic lumen, frequently located between the origin of the left subclavicular artery and the junction of aorta and ductus arteriosus. This pathology is the most common congenital heart disease with ductal-dependent systemic circulation and is frequently encountered in emergency settings in pediatric cardiology units. Echocardiographic assessment of this condition could be difficult in the fetus and newborn, due to the presence of persistent ductus arteriosus (PDA), which alters the anatomy of the aortic lumen, making it difficult to appreciate the narrowing degree of the aortic isthmus.^{1,2}

The ductus arteriosus plays a key role in cardiovascular physiology in both fetuses and newborns. During pregnancy, the ductus arteriosus remains open as a result of several vasodilator systems, such as endogenous prostaglandins, carbon monoxide, nitric oxide, or low pO₂, which inhibit the contractile mechanisms.³ In 90% of full-term newborns, the ductus arteriosus closes and turns into the arterial ligament during the first 48 hours after birth.⁴ Often, a coarctation can be detected only when the ductus arteriosus closes and constriction occurs at the level of juxtaductal region.

In severe forms, this disease represents a critical condition that can become life-threatening, especially in complex cases associated with other congenital heart malformations. Therefore, serial echocardiographic examinations are required for a careful evaluation of the ductus arteriosus anatomy and aortic arch follow-up.^{1,5-7} Usually, aortic coarctation is established by corroborating information provided by general clinical examination with the results of transthoracic echocardiography.

Due to the high influence of the PDA in aortic coarctation diagnosis, several studies tried to identify echocardiography-based predictors for aortic coarctation. A carotid artery-subclavian artery index and the ratio between the diameter of the aortic isthmus and the diameter of the descending aorta have been proved to represent relevant parameters for characterization of aortic coarctation, even in the presence of ductus arteriosus.

The aim of this study was to evaluate the usefulness of different echocardiographic parameters in the prediction of aortic coarctation in newborns.

MATERIAL AND METHOD

This is a retrospective study performed by reviewing echocardiographic images of both pre-term and full-term

newborns presented with aortic coarctation to the emergency room of a clinic of pediatric cardiology. The inclusion criteria were: age (0–28 days), diagnosis/suspicion of neonatal aortic coarctation, and the presence of PDA. The data was obtained by reviewing echocardiographic imaging and protocols. The measured echocardiographic parameters were: diameter of the aortic and mitral annulus, diameter of the innominate artery, diameter of the ascending aorta, diameter of the proximal aortic arch, diameter of the left common carotid artery, diameter of the transverse portion of the aortic arch, diameter of the aortic isthmus, diameter of the descending aorta at diaphragm level, diameter of the arterial ductus, diameter of the pulmonary artery, shunt direction through the PDA, persistence of diastolic gradient in the descendent aorta, distance between the innominate artery and the left common carotid artery, distance between the left common carotid artery and the left subclavicular artery. Based on echocardiographic measurements, both the common carotid artery-subclavian artery index (CSAi) and the aortic isthmus-descending aorta index (I/D) were calculated. CSAi represents the ratio between of the aortic arch diameter at the level of subclavian artery to the distance between the left common carotid artery and the left subclavian artery, while I/D is the ratio between aortic isthmus and descending aorta diameters.^{8,9} The Z score was also calculated by correlating body surface area and aortic annulus diameter, mitral annulus, distal portion of the aortic arch, and aortic isthmus using the Detroit calculation formula. Newborn demographic data analyzed included: gender, mean age at the time of the first echocardiographic evaluation, mean weight, mean length, average body surface area, mean gestational age, and antenatal diagnosis.

All the study procedures were performed in accordance with the declaration of Helsinki and the analysis protocol was approved by the institutional board of the hospital.

STATISTICAL ANALYSIS

The data were analyzed using MedCalc (MedCalc Software, Ostend, Belgium) and GraphPad Prism (GraphPad Software, San Diego, USA) softwares. Data were classified as nominal or quantitative variables. The nominal variables were characterized by the use of frequencies. The quantitative variables were tested for distribution normalization using the Kolmogorov-Smirnov test and were characterized by averages and percentiles (25–75%) or by mean and standard deviation (SD), if any. The chi-square test was used to verify if there was a statistical significance between two characteristics (lesion type and diagnosis).

Quantitative variables were compared using the Student test. Descriptive statistics were used to analyze the most common congenital heart disease associated. In order to appreciate the predictability of the two indices, the ROC curve was used, calculating the areas under the curve and generating characteristic values of the variables for each significant predictor. The level of significance of the statistics was set at $p < 0.05$.

RESULTS

All data of 703 newborns were evaluated, of which 52 newborns presented in acute settings were classified as having aortic coarctation and included in the study. After data extraction, the study group was divided into 3 subgroups: subgroup 1 – 26 newborns diagnosed with ductal-dependent aortic coarctation who subsequently underwent surgical correction in the neonatal period; subgroup 2 – 2 newborns diagnosed with non-ductal-dependent aortic coarctation who benefited from surgical correction at ages ranging from 1 month to 1 year; and subgroup 3 – 24 newborns with unconfirmed aortic coarctation. In group 1, 21 patients had the diagnosis established at the first echocardiographic evaluation, even in the presence of PDA, while patients from group 2 and 3 were diagnosed between 2 and 11 echocardiographic assessments.

The demographic data of the study are shown in Table 1. The most common associated cardiac anomalies among newborns in group 1 are shown in Table 2. In our study, 18 newborns benefited from antenatal diagnosis of aortic coarctation, and 12 of them belonged to group 1. No data regarding antenatal suspicion or diagnosis could be identified in 10 newborns.

Echocardiographic assessment identified statistically significant differences between the three groups of patients, patients in group 1 presenting smaller mean diam-

eters of the echocardiographic measurements than patients in group 2 and 3 (Table 3).

ROC analysis identified a cutoff value of 1.37 for the CSAi index and a cutoff value of 0.46 for the I/D index as being associated with the highest predictive power for the diagnosis of aortic coarctation (Figure 1 and Figure 2).

DISCUSSION

The neonatal period is characterized by changes in organ function, especially in the cardiovascular system.¹⁰ The newborn myocardium has a low tolerance in the presence of increased preload and a lower response in case of increased afterload compared to the myocardium of an infant or child, therefore an early and correct diagnosis of aortic coarctation is mandatory for preventing acute deterioration of cardiac function.¹⁰⁻¹³

Establishing the diagnosis of aortic coarctation in newborns in the presence of PDA remains challenging.¹ As a consequence, patients in group 2 and 3 in our study required serial echocardiographic evaluations for establishing an accurate diagnosis and initiation of an appropriate decision-making process.

A similar study conducted by Marrow *et al.* on 14 newborns diagnosed with coarctation of the aorta without association of any other significant cardiac abnormalities, compared with 14 newborns without any cardiac pathology, demonstrated that neonates with aortic coarctation had a smaller diameter of the aortic annulus, transverse portion of the aortic arch, and aortic isthmus; a larger diameter in the innominate artery and a greater distance between the left common carotid artery and the left subclavicular artery between the two batches. They also demonstrated a larger diameter of the pulmonary artery in newborns with coarctation of the aorta.¹⁴

TABLE 1. Demographic data of the study population

Variable	Results
Mean weight (g)	3,159.14
Mean length (cm)	51.66
Mean body surface area (m ²)	0.20
Mean age at first echocardiogram (days)	4.2
Number of echocardiograms performed until final diagnosis (days)	2.51
Mean gestational age (weeks)	37.88
Premature newborns (number)	5
Suspicion/antenatal diagnosis of coarctation of the aorta (%)	42.9

TABLE 2. Frequency of associated congenital heart lesions in group 1 – results are number of patients (% of patients)

Variable	Group 1 n = 23	%
Bicuspid aortic valve	12	52.17
Atrial septal defect	22	95.56
Ventricular septal defect	4	17.39
Subvalvular aortic stenosis	1	4.35
Valvular aortic stenosis	2	8.7
Aortic arch hypoplasia	5	21.74
Borderline LV	2	8.7
Left superior vena cava	5	21.74

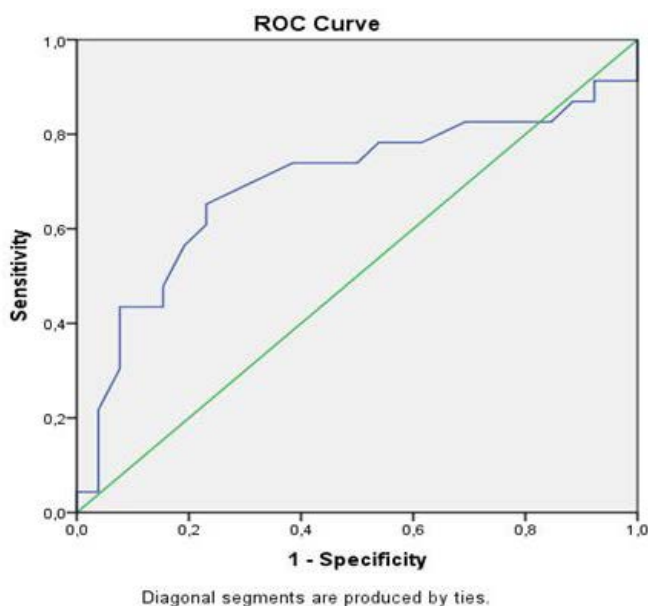
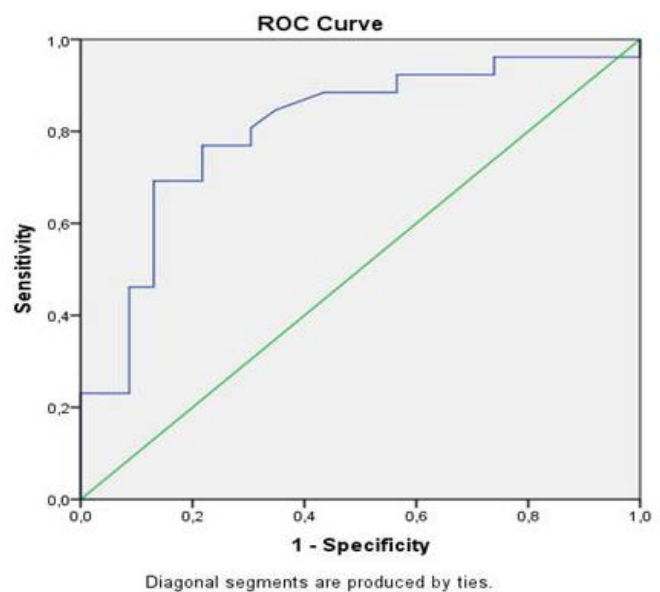
TABLE 3. Average, standard deviation and p value of each echocardiographic parameter in group 1, group 2, and group 3

Variable	Group1	p value	Group 2	p value	Group 3	p value
Aortic valve annulus	0.60 ± 0.07	0.005	0.56 ± 0.05	0.21	0.68 ± 0.10	0.003
Aortic valve annulus Z score	-1.22 ± 1.29	0.72	-1.31 ± 1.38	0.96	-1.73 ± 6.97	0.70
Mitral valve annulus	0.86 ± 0.19	0.08	0.89 ± 0.091	0.87	0.97 ± 0.26	0.10
Mitral valve annulus Z score	-2.21 ± 1.48	0.01	-1.44 ± 0.83	0.77	-1.13 ± 1.33	0.026
Right innominate artery diameter (cm)	0.39 ± 0.11	0.65	0.31 ± 0.007	0.001	0.38 ± 0.13	0.79
Distal ascending aorta diameter (cm)	0.63 ± 0.10	0.031	0.56 ± 0.05	0.16	0.71 ± 0.14	0.029
Proximal transverse arch diameter (cm)	0.48 ± 0.10	0.005	0.46 ± 0.05	0.37	0.57 ± 0.11	0.006
Distance between right innominate and left CCA (cm)	0.27 ± 0.12	0.76	0.25 ± 0.007	0.28	0.29 ± 0.27	0.75
Left common carotid artery diameter (cm)	0.42 ± 0.48	0.13	0.18 ± 0.077	0.49	0.28 ± 0.06	0.19
Distal transverse arch (cm)	0.27 ± 0.74	0.49	0.35 ± 0.00	0.97	0.40 ± 0.58	0.47
Distal transverse arch diameter Z score	-2.38 ± 1.44	0.002	-2.78 ± 0.12	0.001	-1.00 ± 0.84	0.0001
Distance between the left common carotid artery and the left subclavian artery	0.54 ± 0.19	0.058	0.45 ± 0.32	0.93	0.40 ± 0.31	0.091
Carotid-subclavian index	0.89 ± 0.55	0.0001	1.05 ± 0.76	0.69	1.70 ± 0.803	0.001
Aortic isthmus (cm)	0.27 ± 0.11	0.01	0.21 ± 0.09	0.35	0.35 ± 0.07	0.005
Aortic isthmus Z score	-4.43 ± 2.01	0.01	-5.49 ± 2.55	0.50	-2.81 ± 1.64	0.004
Descending aorta at diaphragm	0.60 ± 0.09	0.046	0.59 ± 0.007	0.008	0.66 ± 0.08	0.049
I/D	0.44 ± 0.16	0.08	0.36 ± 0.15	0.21	0.52 ± 0.100	0.037
PDA diameter	0.40 ± 0.13	0.005	0.380 ± 0.02	0.74	0.29 ± 0.12	0.006
Main pulmonary artery diameter (cm)	1.10 ± 0.20	0.04	1.15 ± 0.35	0.66	1.02 ± 0.19	0.033

Another study conducted by Lu *et al.* compared two lots: the first lot consisted of 36 newborns diagnosed with aortic coarctation associated with PDA and the control group consisted of 19 newborns with PDA. The results of this study suggested that an I/D ratio of less than 0.64 represents a strong predictor for aortic coarctation.⁹ Similarly,

our study demonstrated that a value of less than 0.46 is associated with an increased specificity and sensitivity for the diagnosis of aortic coarctation.

Dodge-Khatami *et al.* were the first researchers to describe the CSAi index, demonstrating that an index of less than 1.5 has an increased specificity and sensitivity for

**FIGURE 1.** ROC analysis of the CSAi: AUC = 0.91; CI 82–92%; sensitivity = 87%, specificity = 69.2%**FIGURE 2.** ROC analysis for I/D index: AUC = 69.5%; CI 60.2–70.2%; sensitivity = 65.2 %, specificity = 23.1 %

aortic coarctation diagnosis in children. They studied 63 patients aged up to 3 months who were diagnosed with coarctation of the aorta and a control group of 23 newborns without cardiac abnormalities.⁸ Subsequently, Mivelaz *et al.* analyzed the two indices in two batches: the first group consisted of 68 patients aged 0–18 years with coarctation of the aorta, and the control group consisted of 24 subjects, of which 6 had a PDA. They also demonstrated that a CSAi index of less than 1.5 possesses increased sensitivity and sensitivity in the diagnosis of aortic coarctation in children (0–18 years).¹⁰

Another study, conducted by Peng *et al.* that included 33 full-term newborns with suspicion of coarctation of the aorta in the presence of PDA demonstrated that a CSAi index lower than 0.85 shows a specificity of 0.86 and a sensitivity of 0.83 in terms of predictability of aortic coarctation.¹

In our study, the group was composed of both full-term newborns and premature babies (one newborn at 29 weeks gestational age and one newborn at 36 weeks gestational age), showing that in this clinical setting a CSAi value lower than 1.37 has the best predictability for the diagnosis of aortic coarctation.

Our study has several limitations. First, this is a retrospective study and measurements were made offline, on images recorded by different physicians, which can impact the reliability of the measurements. Secondly, as the study lot was not very large, validation of our results is necessary in future prospective studies on a larger number of patients.

CONCLUSION

The CSAi and I/D indices are simple and accessible echocardiographic parameters that can provide supplemental information for the pediatric cardiologist in acute cases of newborns with suspicion of aortic coarctation. These new indices can contribute to the decision-making process in case of pre-term and full-term newborns with suspicion of coarctation of the aorta, independent of the presence of persistent ductus arteriosus. An early diagnosis of these critical cases can contribute to a decreased hospitalization period, subsequently decreasing both staff and material resources.

CONFLICT OF INTEREST

Nothing to declare.

ACKNOWLEDGEMENT

Daniela Toma and Simina-Elena Rusu contributed equally to this work.

REFERENCES

- Peng DM, Punn R, Maeda K, Selamet Tierney ES. Diagnosing Neonatal Aortic coarctation in the setting of Patent Ductus Arteriosus. *Ann Thorac Surg.* 2016;101:1005–1010. doi: 10.1016/j.athoracsur.2015.09.050.
- Rudolph AM. *Congenital diseases of the heart: Clinical-psychological considerations.* Chichester, UK: Wiley-Blackwell; 2009.
- Hubert A, Ford-Chessel C, Berthiller J, Peretti N, Javouhey E, Valla FV. Nutritional status in pediatric intermediate care: Assessment at admission, progression during the stay and after discharge. *Arch Pediatr.* 2016;23:333–339. doi: 10.1016/j.arcped.2015.12.014.
- Krishnan US. Approach to congenital heart disease in the neonate. *Indian J Pediatr.* 2002;69:501–505.
- Massin MM, Deessy H. Delayed recognition of congenital heart disease. *Postgrad Med J.* 2006;82:468–470. doi: 10.1136/pgmj.2005.044495.
- Ramaciotti C, Chin AJ. Noninvasive diagnosis of coarctation of the aorta in the presence of patent ductus arteriosus. *Am Heart J.* 1993;125:179–185.
- Jaquiss RDB, Frommelt PC. Carotid-subclavian artery index: new echocardiographic index to detect coarctation in neonates and infants. Invited commentar. *Ann Thorac Surg.* 2005;80:1657–1658.
- Dodge-Khatami A, Ott S, Di Bernardo S, Berger F. Carotid-subclavian artery index: new echocardiographic index to detect coarctation in neonates and infants. *Ann Thorac Surg.* 2005;80:1652–1621.
- Lu CW, Wang JK, Chang CI, et al. Noninvasive diagnosis of aortic coarctation in neonates with patent ductus arteriosus. *J Pediatr.* 2006;148:217–221. doi: 10.1016/j.jpeds.2005.09.036.
- Mivelaz Y, Di Bernardo S, Meijboom EJ, Sekarski N. Validation of two echocardiographic indexes to improve the diagnosis of complex coarctations. *Eur J Cardiothorac Surg.* 2008;34:1051–1056. doi: 10.1016/j.ejcts.2008.07.036.
- Reller MD, Morton MJ, Giraud GD. Severe right ventricular pressure loading in fetal sheep augments global myocardial blood flow to submaximal levels. *Circulation.* 1992;86:581–588.
- Romero TE, Friedman WF. Limited left ventricular response to volume overload in the neonatal period: a comparative study with the adult animal. *Pediatr Res.* 1979;13:910–915.
- Thornburg KI, Morton MJ. Filling and arterial pressure as determinants of RV stroke volume in the sheep fetus. *Am J Physiol.* 1983;244:H656.
- Morrow Wr, Huhta JC, Murphy DJ Jr, McNamara DG. Quantitative morphology of the aortic arch in neonatal coarctation. *J AM Coll Cardiol.* 1986;8:616–620.